



**PATIENT PRESENTING CLINICAL SIGNS**

Luna Monoz Pet is here because she can't put weight on left paw, and she can't breath well, choking a lot looks like asthma.

**SPECIES RADIOGRAPHIC STUDY OF THE THORAX & ABDOMEN**

Canine A complete set of radiographs of the thorax and abdomen is provided for review.

**BREED RADIOGRAPHIC FINDINGS**

Mixed The body condition score is 9/9.

**SEX** The surrounding bony structures are within normal limits.

Female The extrathoracic soft tissues present homogeneous without abnormalities.

**AGE** The heart is of normal size and shape, there is no evidence of cardiac chamber or vascular enlargement. The pulmonary vasculature is within normal limits.

8 Years The cranial mediastinum presents the expected soft tissue opacity. The mediastinal width is less than twice the width of the vertebral column at the same level.

**INTERPRETED BY** The trachea is normal in diameter and presents the anticipated course. The luminal outline of the trachea is smooth.  
Sebastian Schaub, DVM  
Dr. med. vet. DipECVDI

The lung parenchyma presents the expected architecture and generalized moderate ground glass opacification; the intrapulmonary vascular branching is seen up to the third order lung vessels.

**HOSPITAL NAME** The diaphragm is well delineated with even surface and the expected mild cranial bulging of the diaphragmatic cupola.  
Animal Paradise  
Hospital

Abdomen

**REFERRING VET** The left coxofemoral joint presents moderate osteophyte new bone formation.

Dr. Elshafie No abnormalities of the extraabdominal soft tissues are noted. The abdominal wall is smooth and thin.

**INVOICE** The serosal detail is maintained throughout the peritoneal and retroperitoneal space.

50989 The hepatic volume is mild to moderately increased and the liver is protruding caudally beyond the costal arch.

**DATE** The splenic head is in the anticipated position and within normal limits for size and opacity. The splenic body and tail are considered normal for position, size, shape and opacity.

3-16-22 Both kidneys are seen and present with normal size, shape, delineation and opacity. The urinary bladder is in its anticipated position. No radiopaque calculi are noted throughout the upper and



**PATIENT** lower urinary tract.

Luna Monoz The stomach is in its anticipated position and presents normal content.

**SPECIES** The small intestinal loops are of even diameter and non-dilated, a small amount of gas is seen within the small intestinal loops and considered within normal limits.

Canine The colon is seen in the expected position and presents with appropriate content.

**RADIOGRAPHIC DIAGNOSIS**

- BREED**
- Obesity
  - Hepatomegaly
  - Generalized increased radiopacity of the lung – due to nutritional status
  - Degenerative osteoarthritis coxofemoral joints bilaterally, L>R

**SEX** **INTERPRETATION OF THE FINDINGS & FURTHER RECOMMENDATIONS**

Female The main finding is the obesity, with resultant generalized increased radiopacity of the lung parenchyma. The obesity is also a potential source for impaired pulmonary function due to decreased pulmonary volume and expansibility. No additional specific abnormality is appreciated, explaining the 'choking'. Weight management is considered beneficial.

**AGE**

8 Years Potentials for the hepatomegaly include metabolic hepatic disease/steroid induced hepatopathy, hepatitis or neoplastic infiltration. Ultrasound including FNA sampling can be used as minimally advanced diagnostic tests.

**INTERPRETED BY**

Sebastian Schaub, DVM  
Dr. med. vet. DipECVDI

**HOSPITAL NAME**

Animal Paradise  
Hospital

**REFERRING VET**

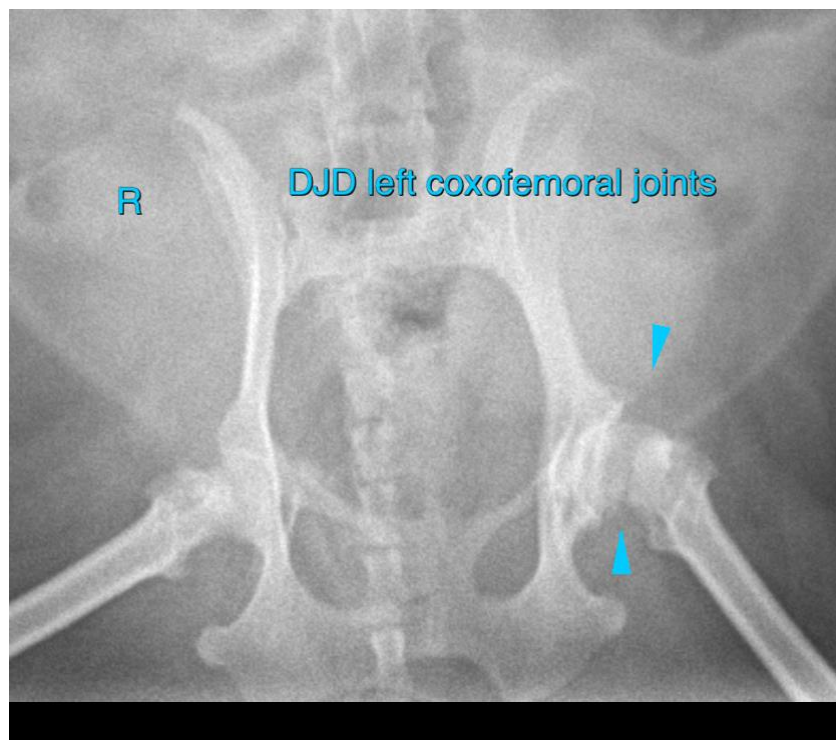
Dr. Elshafie

**INVOICE**

50989

**DATE**

3-16-22





**PATIENT**

Luna Monoz

**SPECIES**

Canine

**BREED**

Mixed

**SEX**

Female

**AGE**

8 Years

**INTERPRETED BY**

Sebastian Schaub, DVM  
Dr. med. vet. DipECVDI

**HOSPITAL NAME**

Animal Paradise  
Hospital

**REFERRING VET**

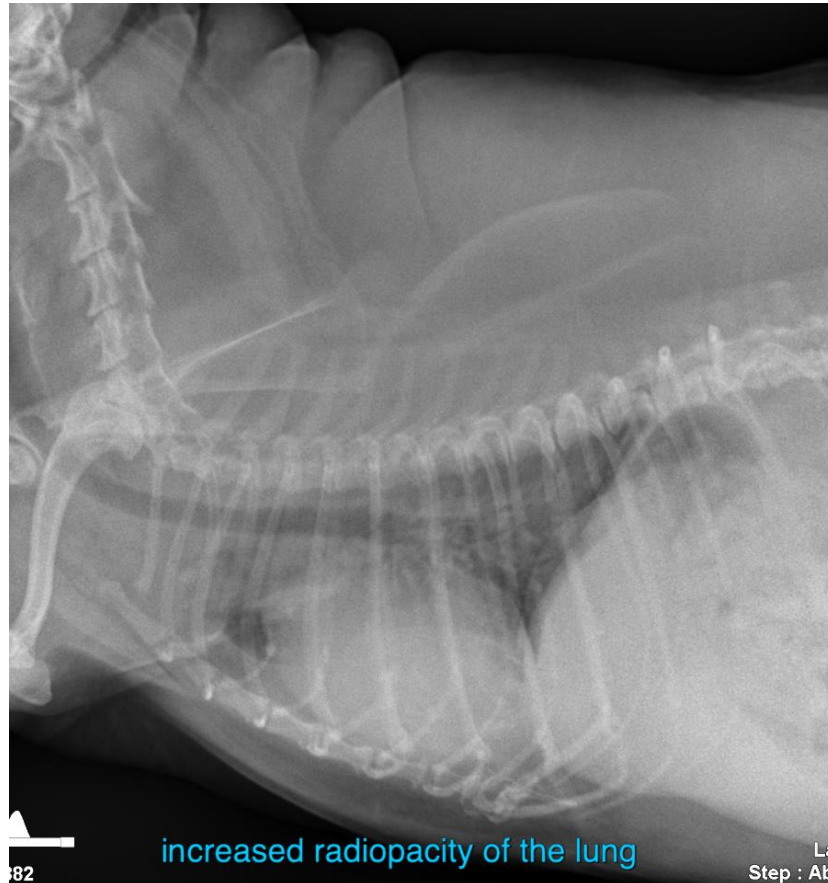
Dr. Elshafie

**INVOICE**

50989

**DATE**

3-16-22



The information and recommendations provided are based on the images presented by the referring veterinarian/sonographer. No evaluation can be communicated regarding pathology that was not visible in the image/video clips provided.

Thank you for this referral. If the clinical or image interpretation does not parallel your findings or if I can be of any further assistance please contact me.

**Sebastian Schaub**, Sebastian Schaub, DVM, Dr. med. vet. DipECVDI  
sebast.schaub@gmail.com