



PATIENT

Harper Fox

PRESENTING CLINICAL SIGNS

History of stiffness and off and on lameness, dog will go for hikes and run hard and then will need 2-3 days to recover.
Abnormal PE/Chem/CBC/UA Results: All WNL.

SPECIES

Canine

RADIOGRAPHIC STUDY OF THE ELBOW AND STIFLE JOINTS

Radiographs of both elbow joints and the right stifle joint in a mediolateral projection are provided for review. Radiographs are provided in JPEG file format.

BREED

Queensland Blue Healer

RADIOGRAPHIC FINDINGS

The periarticular bones of both elbow joints present moderate to marked osteophyte new bone formation. A roundish well defined body is superimposed on the cranioproximal aspect of both elbow joints. The medial coronoid process cannot be delineated.

SEX

Female Spayed

Both fabella present moderate, mild irregular, new bone formation. The remainder of the osseous and soft tissue structures of the right stifle joint are within normal limits.

RADIOGRAPHIC DIAGNOSIS

- Advanced degenerative osteoarthritis elbow joints bilaterally
- Coronoid disease elbow joints bilaterally
- Suspect synovial osteochondromatosis elbow joints bilaterally
- Osseous remodeling fabellae right stifle joint

AGE

7 Years

INTERPRETED BY

Sebastian Schaub, DVM
Dr. med. vet. DipECVDI

INTERPRETATION OF THE FINDINGS & FURTHER RECOMMENDATIONS

The findings are consistent with advanced chronic degenerative joint disease of both elbow joints, underlying pathology of the medial coronoid process (e.g. FCP) is considered likely. The mineralized body at the cranioproximal aspect likely represents synovial osteochondromatosis – an incidental finding. CT can be used as advanced imaging modality for further workup.

HOSPITAL NAME

Branchville Country Vet

The mineralization along the fabellae – suspect medial & lateral – can indicate enthesopathy of the right gastrocnemius muscle.

REFERRING VET

Dr. Sherri Talbot-Valerio

INVOICE

50973

DATE

3-16-22



PATIENT

Harper Fox

SPECIES

Canine

BREED

Queensland Blue Healer

SEX

Female Spayed

AGE

7 Years

INTERPRETED BY

Sebastian Schaub, DVM
Dr. med. vet. DipECVDI

HOSPITAL NAME

Branchville Country Vet

REFERRING VET

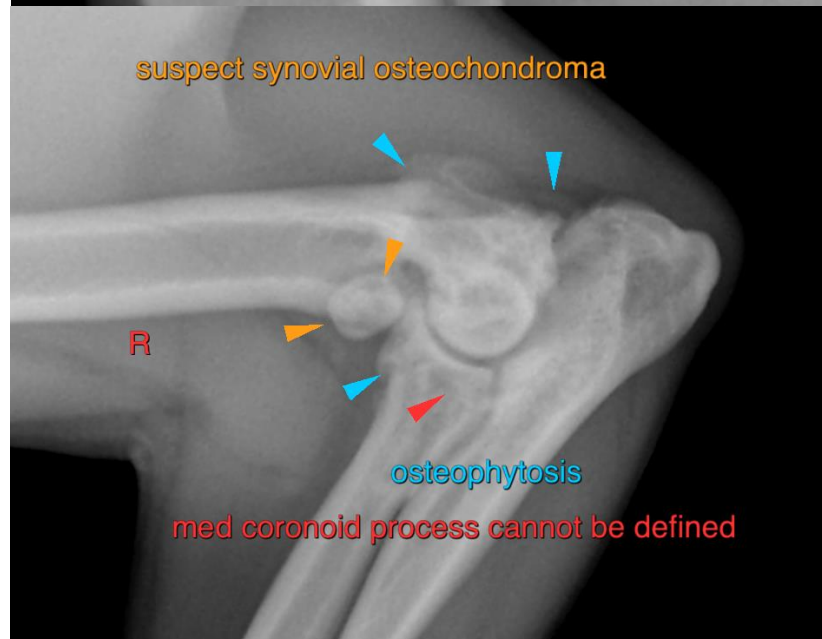
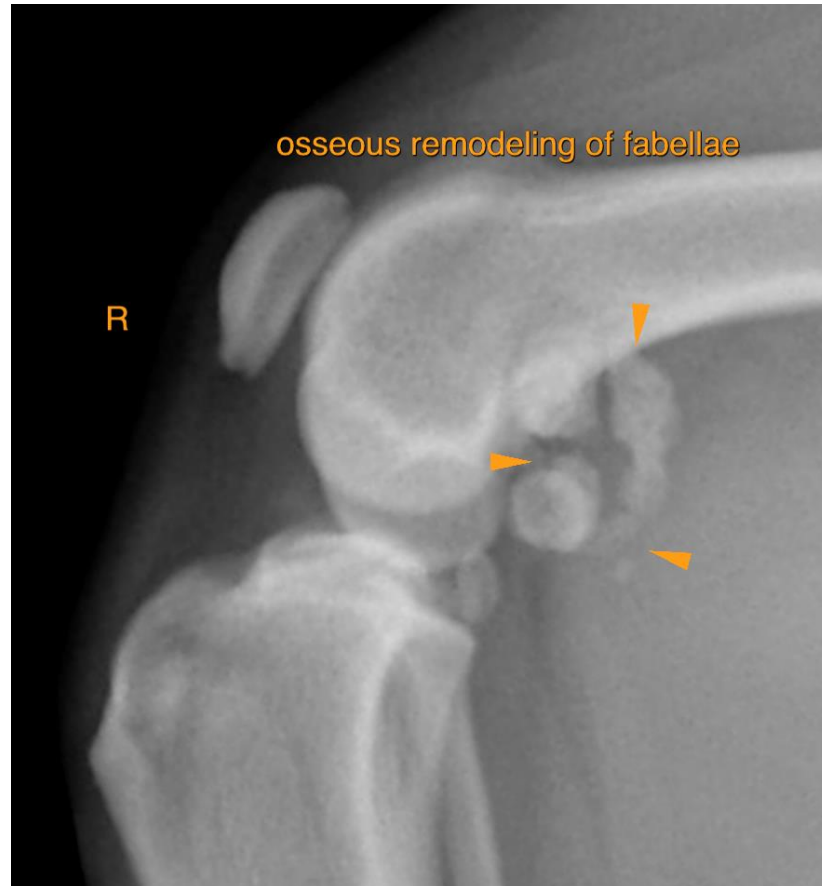
Dr. Sherri Talbot-Valerio

INVOICE

50973

DATE

3-16-22





PATIENT

Harper Fox

SPECIES

Canine

BREED

Queensland Blue
Healer

SEX

Female Spayed

AGE

7 Years

INTERPRETED BY

Sebastian Schaub, DVM
Dr. med. vet. DipECVDI

HOSPITAL NAME

Branchville Country
Vet

REFERRING VET

Dr. Sherri Talbot-
Valerio

INVOICE

50973

DATE

3-16-22

The information and recommendations provided are based on the images presented by the referring veterinarian/sonographer. No evaluation can be communicated regarding pathology that was not visible in the image/video clips provided.

Thank you for this referral. If the clinical or image interpretation does not parallel your findings or if I can be of any further assistance please contact me.

Sebastian Schaub, Sebastian Schaub, DVM, Dr. med. vet. DipECVDI
sebast.schaub@gmail.com