

**PATIENT PRESENTING CLINICAL SIGNS**

Farruk Beato Pt presented in Dec for limping on rt hind. On PE in Dec there was some resistance in extension of rt hip. Pt was given rimadyl and told strict rest, but limping not improving.

SPECIES RADIOGRAPHIC STUDY OF THE PELVIS AND STIFLE JOINTS

Canine Radiographs of the pelvis in a ventrodorsal projection and the stifle joints in two orthogonal imaging planes are provided for review.

RADIOGRAPHIC FINDINGS

BREED
Rottweiler The periarticular bones of both coxofemoral joints present mild osteophyte new bone formation, R>L. The right acetabular groove is shallow and the right coxofemoral joint space is moderately widened. The center of the right femoral head is lateral to the dorsal acetabular rim. The joint space of the left coxofemoral joint is mildly incongruent and mildly diverging medially.

SEX The volume of the soft tissue shadow of the right thigh musculature is moderately decreased in comparison to the contralateral limb.

M Both stifle joints present smooth osseous margins and without signs of an intracapsular soft tissue swelling, unremarkable.

AGE RADIOGRAPHIC DIAGNOSIS

- 1 Year
- Mild degenerative osteoarthritis coxofemoral joints bilaterally, R>L
 - Significant laxity right coxofemoral joint
 - Disuse atrophy right thigh musculature
 - Normal stifle joints

INTERPRETED BY

Sebastian Schaub, DVM
Dr. med. vet. DipECVDI

INTERPRETATION OF THE FINDINGS & FURTHER RECOMMENDATIONS

HOSPITAL NAME
The Pet Hospital of Stratford The radiographic study is consistent with hip dysplasia, R>>L, with significant laxity of the right coxofemoral joint and secondary degenerative osteoarthritis. The findings are a potential source for the right hind limb lameness and surgical options (e.g. total hip replacement) might be discussed with orthopedic surgeon.

REFERRING VET

Dr. Bashkin

INVOICE

57252

DATE

3-15-23



PATIENT

Farruk Beato

SPECIES

Canine

BREED

Rottweiler

SEX

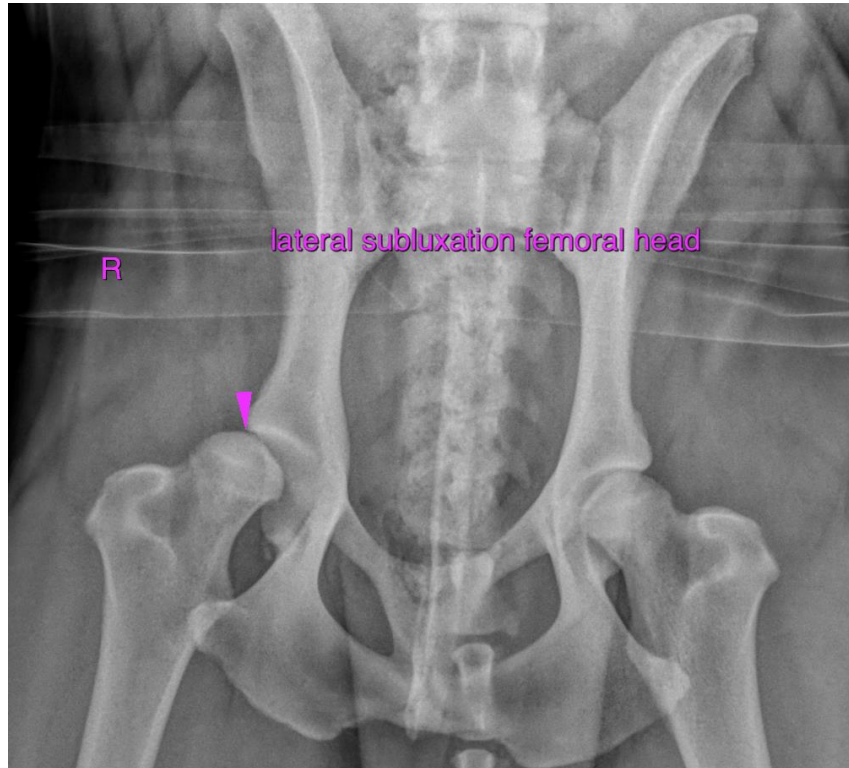
M

AGE

1 Year

INTERPRETED BY

Sebastian Schaub, DVM
Dr. med. vet. DipECVDI



HOSPITAL NAME

The Pet Hospital of
Stratford

The information and recommendations provided are based on the images presented by the referring veterinarian/sonographer. No evaluation can be communicated regarding pathology that was not visible in the image/video clips provided.

Thank you for this referral. If the clinical or image interpretation does not parallel your findings or if I can be of any further assistance please contact me.

REFERRING VET

Dr. Bashkin

Sebastian Schaub, Sebastian Schaub, DVM, Dr. med. vet. DipECVDI
sebast.schaub@gmail.com

INVOICE

57252

DATE

3-15-23