



**PATIENT PRESENTING CLINICAL SIGNS**

Cookie Rivera Pt has large, doughy at palpation growth on left inguinal fold. Unable to reduce possible hernia, rads prior to cytology to r/o intestinal involvement.

**SPECIES RADIOGRAPHIC STUDY OF THE ABDOMEN**

Canine Radiographs of the abdomen in three imaging planes are provided for review.

**BREED RADIOGRAPHIC FINDINGS**

Bichon Frise Mix Superimposed on the ventral aspect of the neuroforamina L1/L2 to L3/L4 and L6/L7, convex shaped mineralized material is seen.

**SEX** Multiple small gas inclusions are seen in the subcutaneous tissue at the craniolateral aspect of the right thigh.

F The serosal detail is maintained throughout the peritoneal and retroperitoneal space.

**AGE** The liver is appropriate in position, size and presents uniform opacity.

7.5 Years The splenic head is in the anticipated position and within normal limits for size and opacity. The splenic body and tail are considered normal for position, size, shape and opacity.

**INTERPRETED BY** Both kidneys are seen and present with normal size, shape, delineation and opacity. The urinary bladder is in its anticipated position. No radiopaque calculi are noted throughout the upper and lower urinary tract.

Sebastian Schaub, DVM  
Dr. med. vet. DipECVDI

The stomach is in its anticipated position and presents normal content.

**HOSPITAL NAME** The small intestinal loops are of even diameter and non-dilated, a small amount of gas is seen within the small intestinal loops and considered within normal limits.

The Pet Hospital of  
Stratford

The colon is seen in the expected position and presents with appropriate content.

**RADIOGRAPHIC DIAGNOSIS**

- REFERRING VET**
- Left sided inguinal hernia with central tubular structure
  - Suspect intervertebral disc protrusion L1/L2 to L3/L4 and L6/L7

Dr. Giuliani

**INTERPRETATION OF THE FINDINGS & FURTHER RECOMMENDATIONS**

**INVOICE** The radiographic findings are supporting the diagnosis of left sided inguinal hernia with a central tubular structure – the tubular structure can present the left uterine horn, due to the lack of intraluminal gas the odds for herniated small intestinal loop are considered lower. Anyway herniation ± incarceration of a small intestinal loop or the uterus may happen anytime. Surgical management is recommended.

57253

**DATE**

3-15-23



**PATIENT**

Cookie Rivera

**SPECIES**

Canine

**BREED**

Bichon Frise Mix

**SEX**

F

**AGE**

7.5 Years

**INTERPRETED BY**

Sebastian Schaub, DVM  
Dr. med. vet. DipECVDI

**HOSPITAL NAME**

The Pet Hospital of  
Stratford

**REFERRING VET**

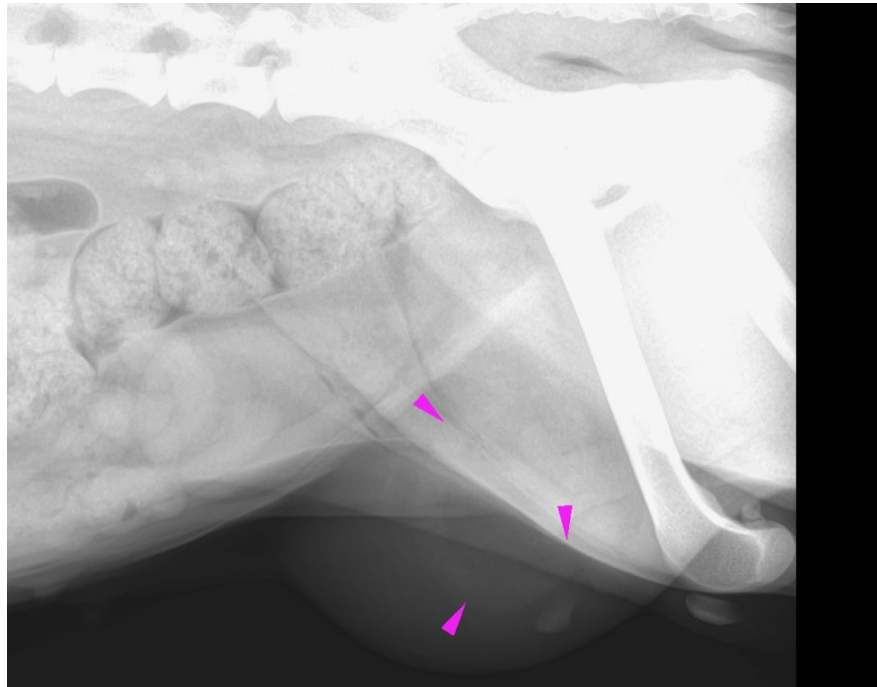
Dr. Giuliani

**INVOICE**

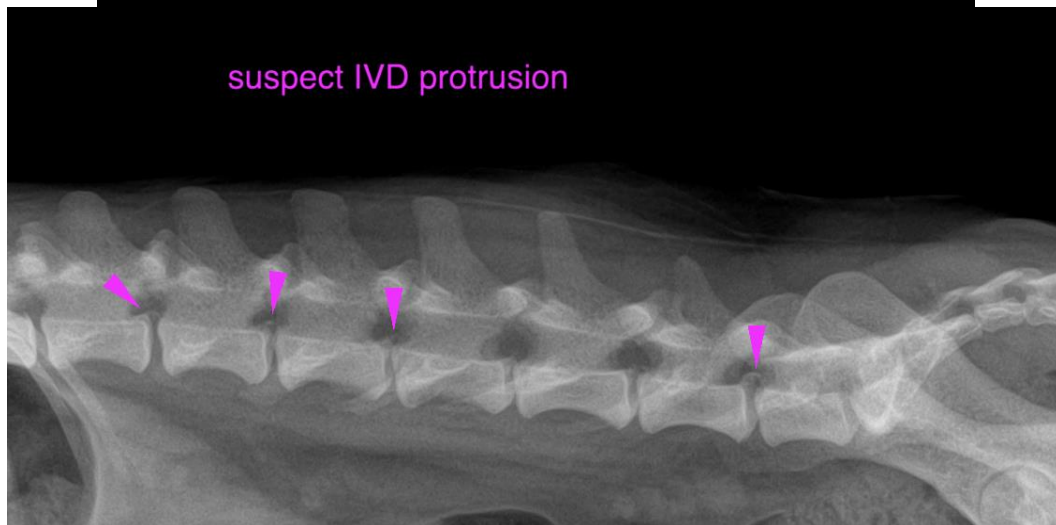
57253

**DATE**

3-15-23



swelling with central tubular soft tissue structure



suspect IVD protrusion



**PATIENT**

Cookie Rivera

**SPECIES**

Canine

**BREED**

Bichon Frise Mix

**SEX**

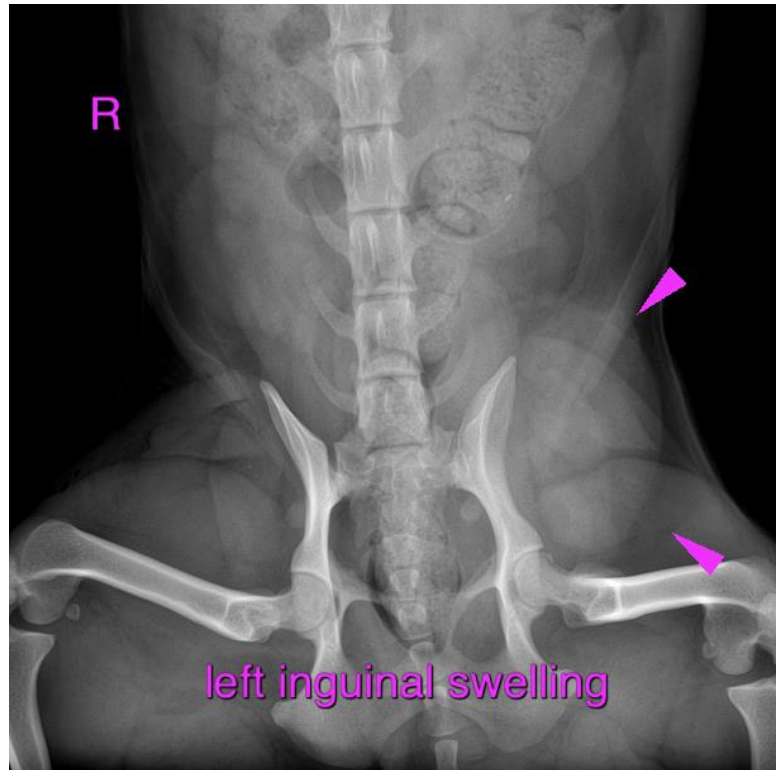
F

**AGE**

7.5 Years

**INTERPRETED BY**

Sebastian Schaub, DVM  
Dr. med. vet. DipECVDI



**HOSPITAL NAME**

The Pet Hospital of  
Stratford

The information and recommendations provided are based on the images presented by the referring veterinarian/sonographer. No evaluation can be communicated regarding pathology that was not visible in the image/video clips provided.

Thank you for this referral. If the clinical or image interpretation does not parallel your findings or if I can be of any further assistance please contact me.

**REFERRING VET**

Dr. Giuliani

**Sebastian Schaub**, Sebastian Schaub, DVM, Dr. med. vet. DipECVDI  
sebast.schaub@gmail.com

**INVOICE**

57253

**DATE**

3-15-23