

**PATIENT**

Shelby Gonzales

PRESENTING CLINICAL SIGNS

sedated radiographs to compare to previous study on 3/3/22, further evaluation of multipartite sesamoid bones and possible elbow dysplasia of right forelimb. Limping is persistent of right forelimb, no response to rimadyl and gabapentin therapy.

SPECIES

Canine

Abnormal PE/Chem/CBC/UA Results: WNL

RADIOGRAPHIC STUDY OF THE FRONT LIMBS

A complete set of radiographs of the front limbs is provided for review.

BREED

Rottweiler

RADIOGRAPHIC FINDINGS

Both shoulder joints present smooth osseous margins, stationary.

SEX

SF

A mild double opacity is seen at the dorsal aspect of the anconeal process bilaterally. The medial coronoid process is ill-defined. At the base of the medial coronoid bilaterally, moderate sclerosis is noted.

AGE

9 Months

The abaxial sesamoid bone of the right metacarpophalangeal joint of the second phalanx is multipartite, stationary.

No abnormalities of the left front paw are appreciated in the current study.

INTERPRETED BYSebastian Schaub, DVM
Dr. med. vet. DipECVDI**RADIOGRAPHIC DIAGNOSIS**

- Suspect coronoid pathology elbow joints bilaterally
- Mild degenerative osteoarthritis elbow joints bilaterally
- Multipartite abaxial sesamoid bone right metacarpophalangeal joint of the second phalanx
- Normal shoulder joints

HOSPITAL NAMERockaway Animal
Hospital**INTERPRETATION OF THE FINDINGS & FURTHER RECOMMENDATIONS**

The radiographic findings of the elbow joints are concerning for underlying pathology of the medial coronoid process (e.g. FCP) with secondary mild degenerative osteoarthritis. Complementing workup by a CT study would be ideal for further definition.

REFERRING VET

Dr. Kahn

INVOICE

50924

DATE

3-15-22



PATIENT

Shelby Gonzales

SPECIES

Canine

BREED

Rottweiler

SEX

SF

AGE

9 Months

INTERPRETED BY

Sebastian Schaub, DVM
Dr. med. vet. DipECVDI

HOSPITAL NAME

Rockaway Animal
Hospital

REFERRING VET

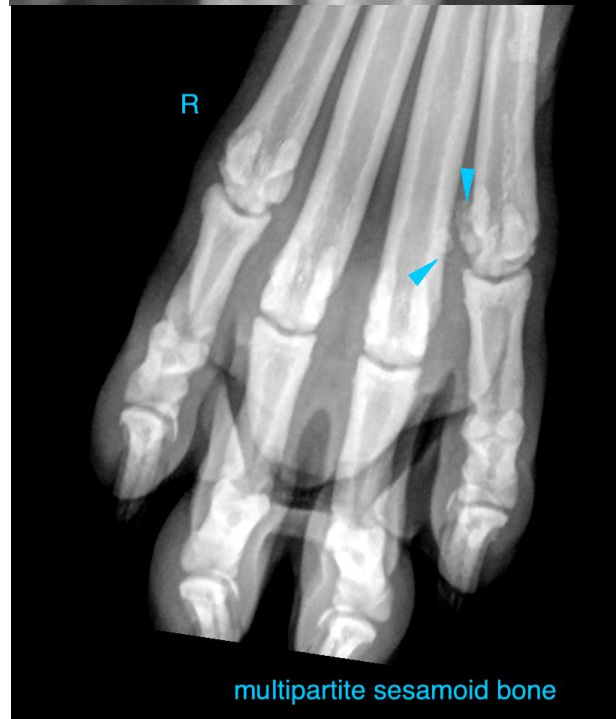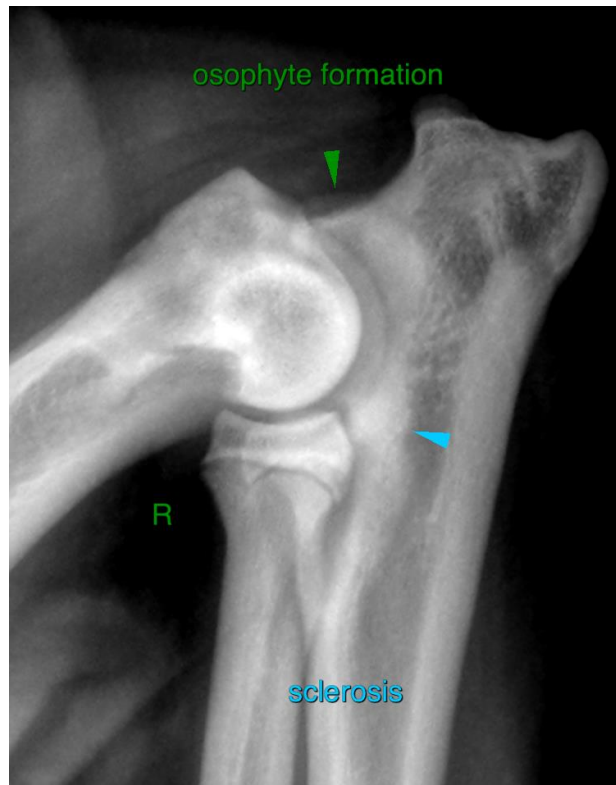
Dr. Kahn

INVOICE

50924

DATE

3-15-22





PATIENT

Shelby Gonzales

SPECIES

Canine

BREED

Rottweiler

SEX

SF

AGE

9 Months

INTERPRETED BY

Sebastian Schaub, DVM
Dr. med. vet. DipECVDI

HOSPITAL NAME

Rockaway Animal
Hospital

REFERRING VET

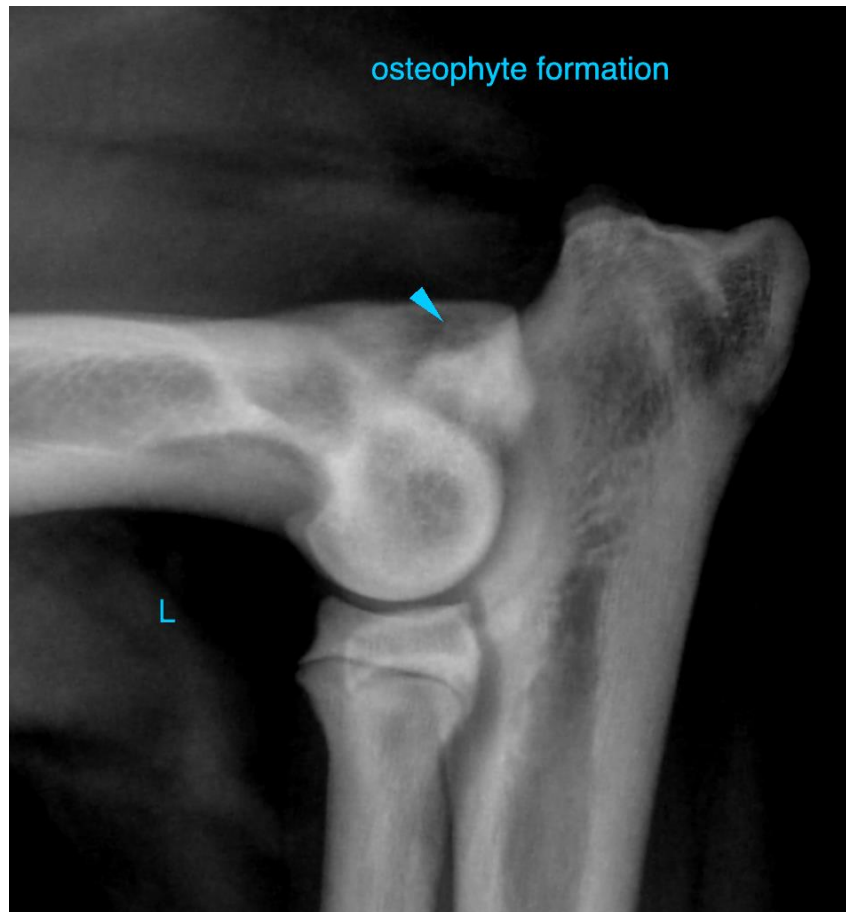Dr. Kahn

INVOICE

50924

DATE

3-15-22



The information and recommendations provided are based on the images presented by the referring veterinarian/sonographer. No evaluation can be communicated regarding pathology that was not visible in the image/video clips provided.

Thank you for this referral. If the clinical or image interpretation does not parallel your findings or if I can be of any further assistance please contact me.

Sebastian Schaub, Sebastian Schaub, DVM, Dr. med. vet. DipECVDI
sebast.schaub@gmail.com