



PATIENT

Koda Pilkington

PRESENTING CLINICAL SIGNS

Fever, anorexia, pain in lumbar/pelvic area

SPECIES

Canine

RADIOGRAPHIC STUDY OF THE CAUDAL ABDOMEN & PELVIS

Radiographs of the pelvis, including the caudal abdomen in two imaging planes are provided for review.

BREED

Shep Mix

RADIOGRAPHIC FINDINGS

The subcutaneous fat dorsal to the lumbar spine presents a marmorated soft tissue opacification.

The serosal detail is maintained throughout the peritoneal and retroperitoneal space.

SEX

Male

The small intestinal loops are of even diameter and non-dilated, a small amount of gas is seen within the small intestinal loops and considered within normal limits.

The urinary bladder is in a relative caudal position extending into the pelvic canal.

AGE

5

The colon is seen in the expected position and presents with appropriate content.

The vertebral endplates L5/L6 and L7/S1 present moderate spondylosis formation.

INTERPRETED BY

Sebastian Schaub, DVM
Dr. med. vet. DipECVDI

Both coxofemoral joints present moderate osteophyte new bone formation, L>R. The acetabular groove bilaterally is shallow, and the center of the femoral heads is lateral to the dorsal acetabular rim.

RADIOGRAPHIC DIAGNOSIS

- Caudal position of the urinary bladder
- Degenerative osteoarthritis coxofemoral joints bilaterally, L>R
- Spondylosis deformans

HOSPITAL NAME

Pacific Avenue
Veterinary Clinic

INTERPRETATION OF THE FINDINGS & FURTHER RECOMMENDATIONS

REFERRING VET

Dr. Sid Bruckert-Frisk

The radiographic study presents no specific abnormality, explaining the fever. Recommend a rectal exam to rule out pathology of the prostate – in neutered male dogs enlargement is highly concerning for neoplastic transformation.

If not done so yet, recommend complete blood work to screen for inflammatory changes.

INVOICE

50937

DATE

3-15-22



PATIENT

Koda Pilkington

SPECIES

Canine

BREED

Shep Mix

SEX

Male

AGE

5

INTERPRETED BY

Sebastian Schaub, DVM
Dr. med. vet. DipECVDI

HOSPITAL NAME

Pacific Avenue
Veterinary Clinic

REFERRING VET

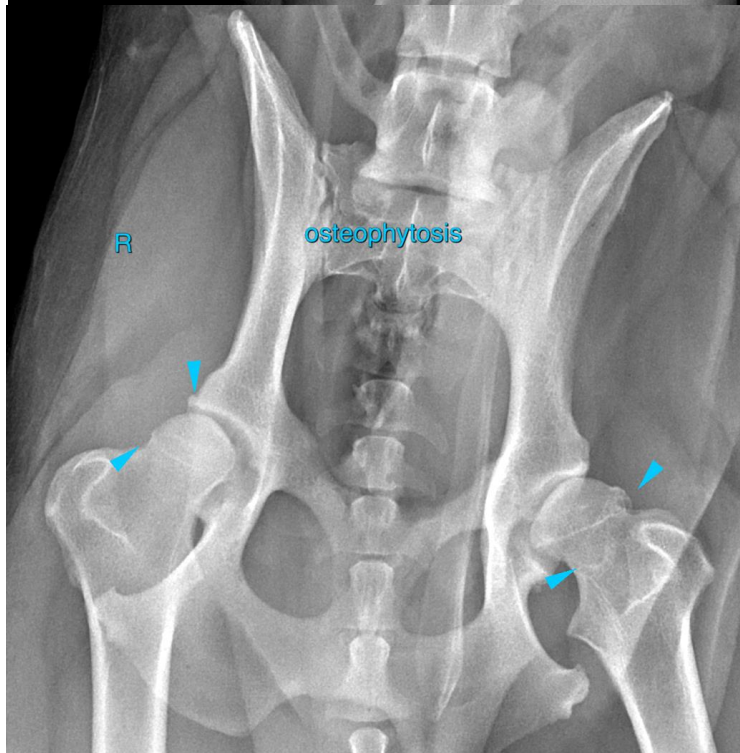
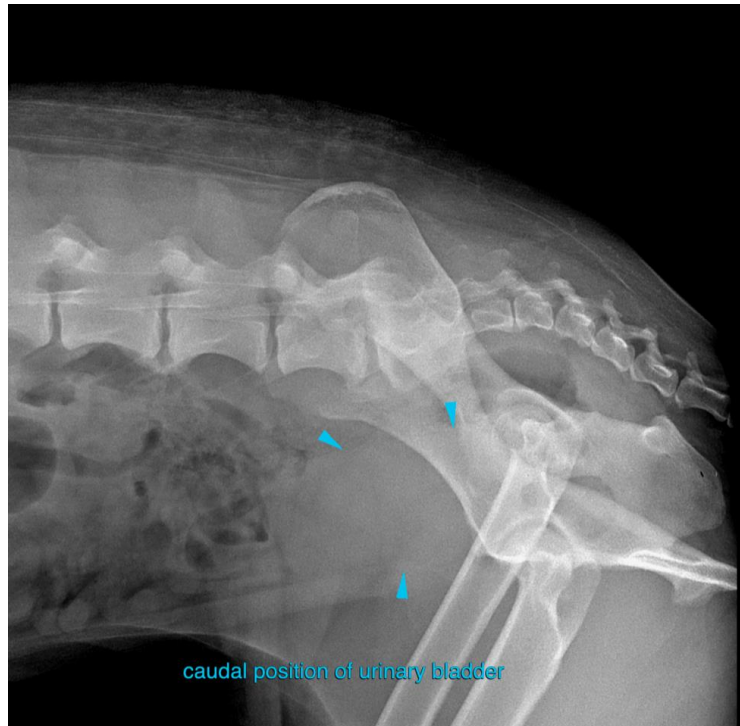
Dr. Sid Bruckert-Frisk

INVOICE

50937

DATE

3-15-22





PATIENT

Koda Pilkington

The information and recommendations provided are based on the images presented by the referring veterinarian/sonographer. No evaluation can be communicated regarding pathology that was not visible in the image/video clips provided.

Thank you for this referral. If the clinical or image interpretation does not parallel your findings or if I can be of any further assistance please contact me.

SPECIES

Canine

Sebastian Schaub, Sebastian Schaub, DVM, Dr. med. vet. DipECVDI
sebast.schaub@gmail.com

BREED

Shep Mix

SEX

Male

AGE

5

INTERPRETED BY

Sebastian Schaub, DVM
Dr. med. vet. DipECVDI

HOSPITAL NAME

Pacific Avenue
Veterinary Clinic

REFERRING VET

Dr. Sid Bruckert-Frisk

INVOICE

50937

DATE

3-15-22