



PATIENT PRESENTING CLINICAL SIGNS

Charlie Karlis Few month lameness left hind pe--butress swelling drawer sign r/o cruciate left hip ? Dysplasia ?

RADIOGRAPHIC STUDY OF THE STIFLE JOINTS

SPECIES Radiographs of the stifle joints in two orthogonal imaging planes.

Canine **RADIOGRAPHIC FINDINGS**

The periarticular bones of both stifle joints present with mild osteophyte new bone formation, L>R. Both stifle joints present a moderate intracapsular soft tissue swelling.

BREED

Labradoodle

RADIOGRAPHIC DIAGNOSIS

- Mild degenerative osteoarthritis stifle joints bilaterally, L>R
- Moderate articular swelling both stifle joints

SEX

Male

INTERPRETATION OF THE FINDINGS & FURTHER RECOMMENDATIONS

The radiographic study is consistent with bilateral mild chronic degenerative osteoarthritis (L>R) with concomitant joint effusion of both stifle joints. The most-likely underlying cause is (partial) rupture of the cranial cruciate ligament with or without meniscal disease. Arthritis – infectious versus immune mediated – is a consideration as well, but the odds are low.

AGE

3 Years

INTERPRETED BY

A positive drawer sign or tibial compression test under general anesthesia can be used to confirm the diagnosis.

Sebastian Schaub, DVM
Dr. med. vet. DipECVDI

HOSPITAL NAME

Tenafly Vet Center

REFERRING VET

Dr. Barnea

INVOICE

57244

DATE

3-14-23



PATIENT

Charlie Karlis

SPECIES

Canine

BREED

Labradoodle

SEX

Male

AGE

3 Years

INTERPRETED BY

Sebastian Schaub, DVM
Dr. med. vet. DipECVDI

HOSPITAL NAME

Tenafly Vet Center

REFERRING VET

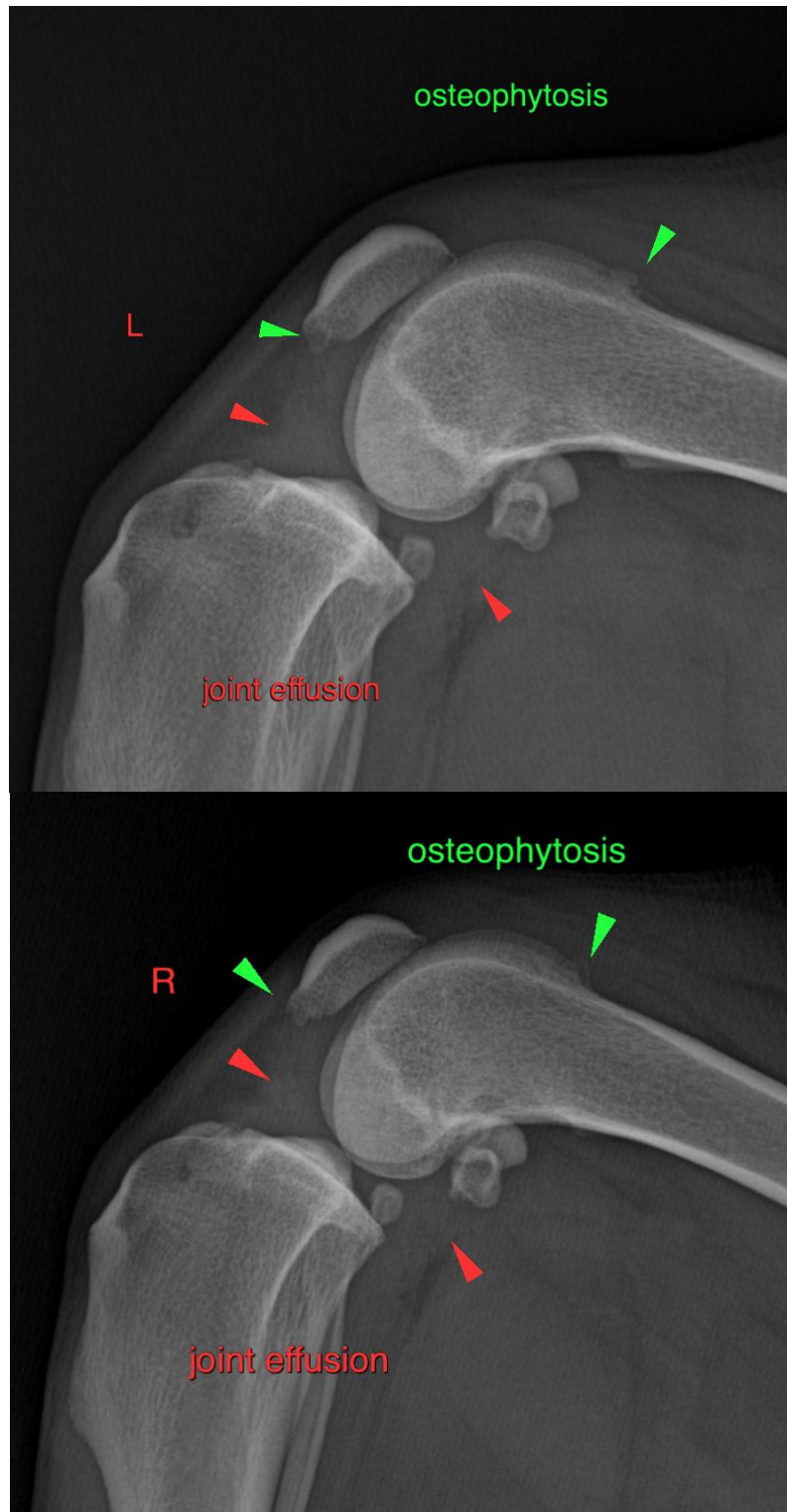
Dr. Barnea

INVOICE

57244

DATE

3-14-23





PATIENT

Charlie Karlis

SPECIES The information and recommendations provided are based on the images presented by the referring veterinarian/sonographer. No evaluation can be communicated regarding pathology that was not visible in the image/video clips provided.

Canine

BREED

Thank you for this referral. If the clinical or image interpretation does not parallel your findings or if I can be of any further assistance please contact me.

Labradoodle

Sebastian Schaub, Sebastian Schaub, DVM, Dr. med. vet. DipECVDI
sebast.schaub@gmail.com

SEX

Male

AGE

3 Years

INTERPRETED BY

Sebastian Schaub, DVM
Dr. med. vet. DipECVDI

HOSPITAL NAME

Tenafly Vet Center

REFERRING VET

Dr. Barnea

INVOICE

57244

DATE

3-14-23