



PATIENT

Vito Gadanidis

PRESENTING CLINICAL SIGNS

began vomiting tonight after dinner, began with bile, then gradually became blood streaked and ultimately was vomiting blood. While in hospital tonight also experienced some blood in stool. Otherwise well until today. Blood work shows elevation in lipase and amylase. Potential pancreatitis but need to rule out foreign body.

SPECIES

Canine

RADIOGRAPHIC STUDY OF THE ABDOMEN

Radiographs of the abdomen in three imaging planes are provided for review.

BREED

Italian Greyhound

RADIOGRAPHIC FINDINGS

The surrounding bony structures are within normal limits.

SEX

Male Neutered

No abnormalities of the extraabdominal soft tissues are noted. The abdominal wall is smooth and thin.

The serosal detail is maintained throughout the peritoneal and retroperitoneal space.

AGE

22 Months

The liver is appropriate in position, size and presents uniform opacity.

The splenic head is in the anticipated position and within normal limits for size and opacity. The splenic body and tail are considered normal for position, size, shape and opacity.

INTERPRETED BY

Sebastian Schaub, DVM
Dr. med. vet. DipECVDI

Both kidneys are seen and present with normal size, shape, delineation and opacity. The urinary bladder is in its anticipated position. No radiopaque calculi are noted throughout the upper and lower urinary tract.

The stomach is in its anticipated position and empty but a mild amount of gas.

HOSPITAL NAME

Truscott Animal Hospital

The small intestinal loops are of even diameter and non-dilated, a small amount of gas is seen within the small intestinal loops and considered within normal limits.

The colon is seen in the expected position and empty.

REFERRING VET

Medhat Meawad

RADIOGRAPHIC DIAGNOSIS

- Empty gastrointestinal tract

INTERPRETATION OF THE FINDINGS & FURTHER RECOMMENDATIONS

INVOICE

50920

The empty gastrointestinal tract in combination with the presenting clinical signs is suggestive for underlying gastroenteritis. There is no evidence of radiopaque foreign material or signs for gastrointestinal mechanical obstruction. Recommend empirical management including dietary changes.

DATE

3-14-22



PATIENT

Vito Gadanidis

SPECIES

Canine

BREED

Italian Greyhound

SEX

Male Neutered

AGE

22 Months

INTERPRETED BY

Sebastian Schaub, DVM
Dr. med. vet. DipECVDI

HOSPITAL NAME

Truscott Animal
Hospital

REFERRING VET

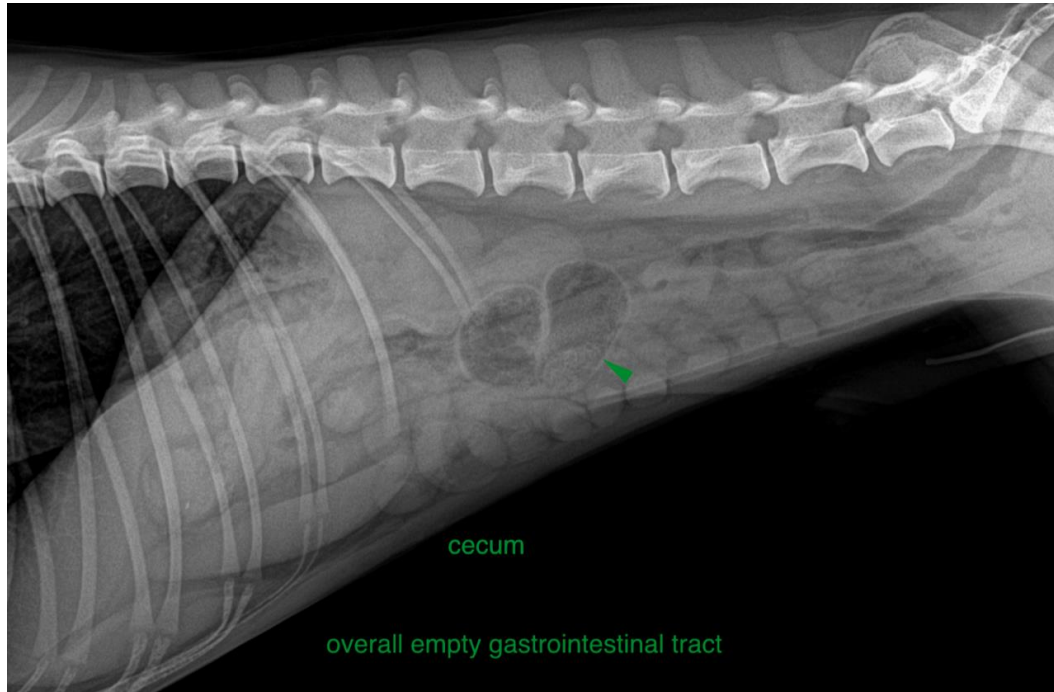
Medhat Meawad

INVOICE

50920

DATE

3-14-22



The information and recommendations provided are based on the images presented by the referring veterinarian/sonographer. No evaluation can be communicated regarding pathology that was not visible in the image/video clips provided.

Thank you for this referral. If the clinical or image interpretation does not parallel your findings or if I can be of any further assistance please contact me.

Sebastian Schaub, Sebastian Schaub, DVM, Dr. med. vet. DipECVDI
sebast.schaub@gmail.com