



PATIENT

Rigby Meunier

PRESENTING CLINICAL SIGNS

Intermittent vomiting for 5 days, severe distension in the stomach. In house ultrasound by RDVM, unable to view the pyloric region.
Abnormal PE/Chem/CBC/UA Results: Normal blood testing

SPECIES

Canine

RADIOGRAPHIC STUDY OF THE ABDOMEN

Radiographs of the abdomen in three imaging planes are provided for review. Radiographs are provided in JPEG file format

BREED

Schnauzer Mix

RADIOGRAPHIC FINDINGS

The surrounding bony structures are within normal limits.

SEX

Male Neutered

No abnormalities of the extraabdominal soft tissues are noted. The abdominal wall is smooth and thin.

The serosal detail is maintained throughout the peritoneal and retroperitoneal space.

AGE

2 Years

The liver is appropriate in position, size and presents uniform opacity.

The splenic head is in the anticipated position and within normal limits for size and opacity. The splenic body and tail are considered normal for position, size, shape and opacity.

INTERPRETED BY

Sebastian Schaub, DVM
Dr. med. vet. DipECVDI

Both kidneys are seen and present with normal size, shape, delineation and opacity. The urinary bladder is in its anticipated position. No radiopaque calculi are noted throughout the upper and lower urinary tract.

The stomach is in its anticipated position and contains a mild to moderate amount of gas.

HOSPITAL NAME

Windermere
Veterinary Hospital

The small intestinal loops are of even diameter and non-dilated, a small amount of gas is seen within the small intestinal loops and considered within normal limits.

The colon is seen in the expected position and presents with appropriate content.

REFERRING VET

Dr. Sherif Boctor

RADIOGRAPHIC DIAGNOSIS

- Mild gas & fluid distended stomach

INVOICE

50911

INTERPRETATION OF THE FINDINGS & FURTHER RECOMMENDATIONS

In the current set of radiographs of the abdomen, only mild distension of the stomach is appreciated. There is no evidence of radiopaque foreign material or signs for gastrointestinal mechanical obstruction. Rule out gastritis as source for the intermittent vomiting with possible gastric emptying disorder. Empirical management with antiemetic drugs and gastric protection therapy appears beneficial.

DATE

3-14-22



PATIENT

Rigby Meunier

SPECIES

Canine

BREED

Schnauzer Mix

SEX

Male Neutered

AGE

2 Years

INTERPRETED BY

Sebastian Schaub, DVM
Dr. med. vet. DipECVDI

HOSPITAL NAME

Windermere
Veterinary Hospital

REFERRING VET

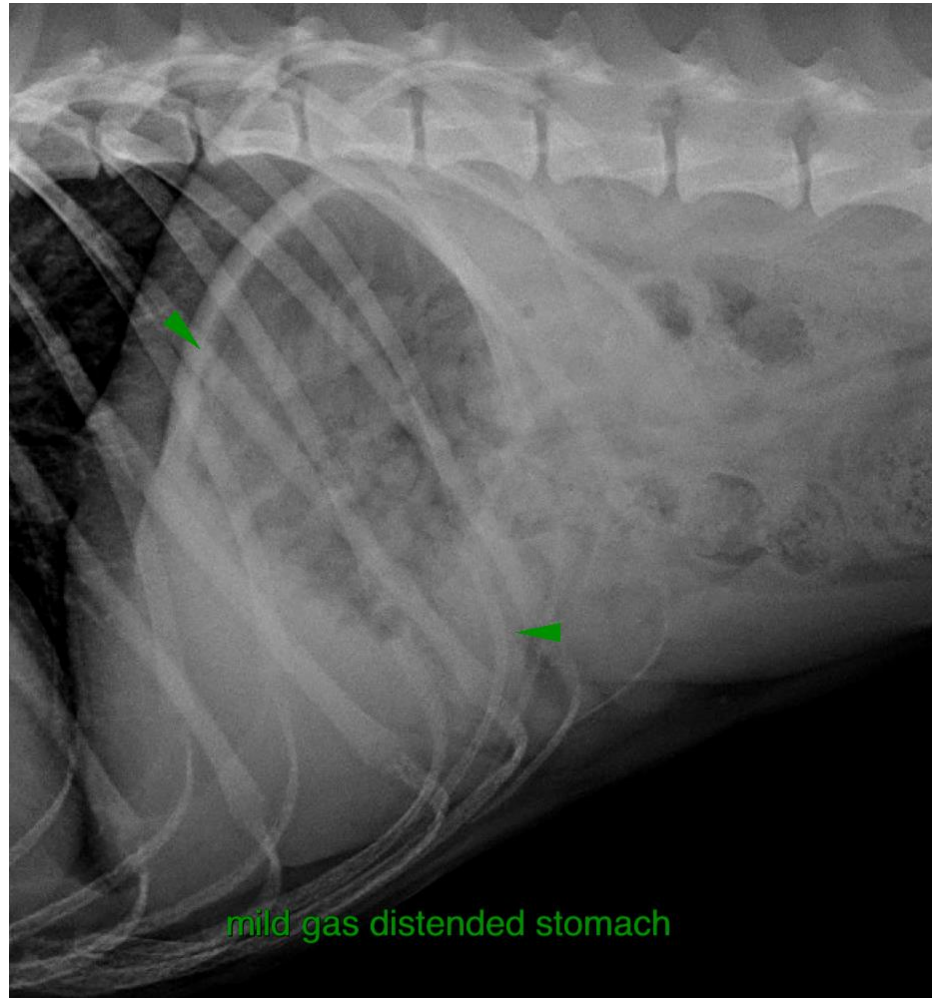
Dr. Sherif Bactor

INVOICE

50911

DATE

3-14-22



The information and recommendations provided are based on the images presented by the referring veterinarian/sonographer. No evaluation can be communicated regarding pathology that was not visible in the image/video clips provided.

Thank you for this referral. If the clinical or image interpretation does not parallel your findings or if I can be of any further assistance please contact me.

Sebastian Schaub, Sebastian Schaub, DVM, Dr. med. vet. DipECVDI
sebast.schaub@gmail.com