



PATIENT PRESENTING CLINICAL SIGNS

Miley Maiato coughing for approximately one month
 Abnormal PE/Chem/CBC/UA Results: Grade 3/6 heart murmur on exam

SPECIES RADIOGRAPHIC STUDY OF THE THORAX

Canine Radiographs of the thorax in three imaging planes are provided for review.

BREED RADIOGRAPHIC FINDINGS

Shih Poo X The surrounding bony structures are within normal limits.
 The extrathoracic soft tissues present homogeneous without abnormalities.

SEX The caudal contour of the cardiac silhouette is steep, and the caudal cardiac waist is lost. The vertebral heart score is 10.7. The pulmonary vasculature is within normal limits.

Spayed Female

The cranial mediastinum presents the expected soft tissue opacity. The mediastinal width is less than twice the width of the vertebral column at the same level.

AGE The trachea is normal in diameter and presents the anticipated course. The luminal outline of the trachea is smooth.

14

INTERPRETED BY The bronchial tree presents with thin walls and tapers uniformly towards the periphery as expected.

Sebastian Schaub, DVM
 Dr. med. vet. DipECVDI

The lung parenchyma presents the expected architecture and opacity; the intrapulmonary vascular branching is seen up to the third order lung vessels.

HOSPITAL NAME The diaphragm is well delineated with even surface and the expected mild cranial bulging of the diaphragmatic cupola.

Truscott Animal Hospital

RADIOGRAPHIC DIAGNOSIS

- Mild left sided cardiomegaly without signs of decompensation

REFERRING VET

Meda Abdelsayed

INTERPRETATION OF THE FINDINGS & FURTHER RECOMMENDATIONS

INVOICE

50922

The mild cardiomegaly, accentuating the left side of the heart in combination with the cardiac murmur is likely a sequela to mitral valve insufficiency – underlying myxomatous mitral valve degeneration is likely. As radiographic changes are mild, the clinical relevance for the cough is unclear. A cardiac echo can be used for further assessment of cardiac chamber size and function.

DATE

3-14-22

No additional abnormalities are appreciated, however, this does not rule out inflammatory lower airway disease such as bronchitis/tracheitis.

TECHNICAL COMMENTS

A gloved hand is seen in the primary beam, please consider radiation safety guidelines.



PATIENT

Miley Maiato

SPECIES

Canine

BREED

Shih Poo X

SEX

Spayed Female

AGE

14

INTERPRETED BY

Sebastian Schaub, DVM
Dr. med. vet. DipECVDI

HOSPITAL NAME

Truscott Animal
Hospital

REFERRING VET

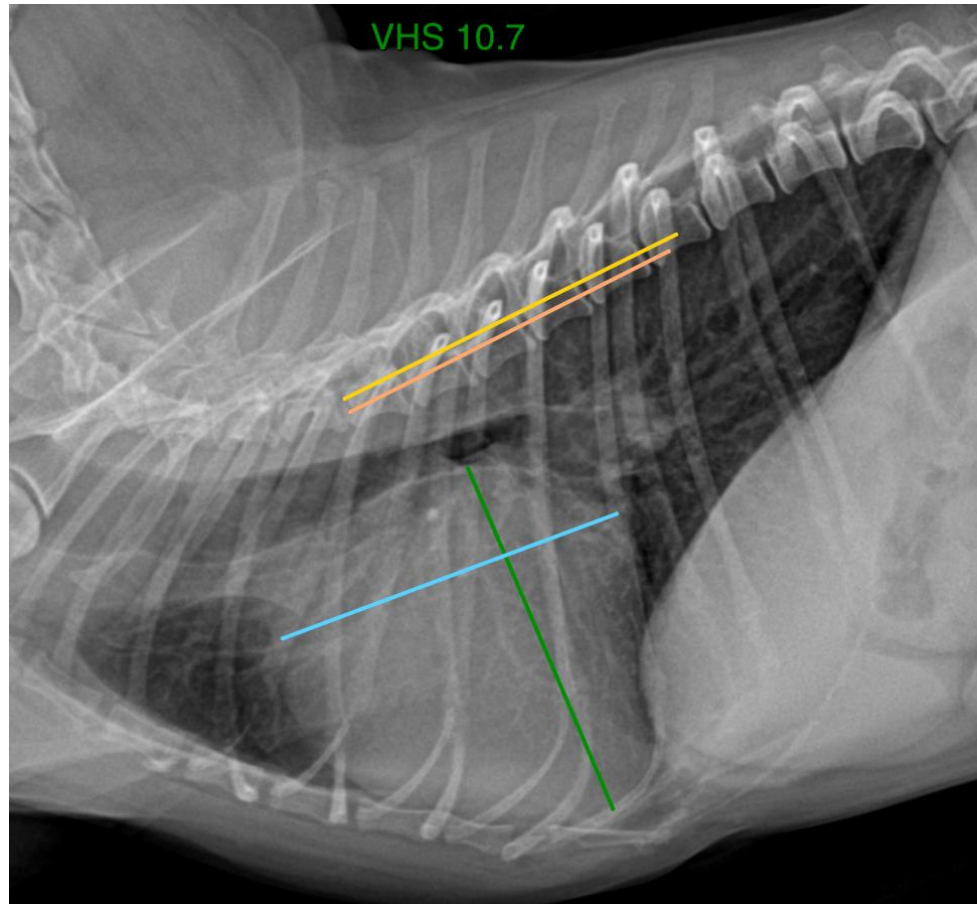
Meda Abdelsayed

INVOICE

50922

DATE

3-14-22



The information and recommendations provided are based on the images presented by the referring veterinarian/sonographer. No evaluation can be communicated regarding pathology that was not visible in the image/video clips provided.

Thank you for this referral. If the clinical or image interpretation does not parallel your findings or if I can be of any further assistance please contact me.

Sebastian Schaub, Sebastian Schaub, DVM, Dr. med. vet. DipECVDI
sebast.schaub@gmail.com