



PATIENT

Logan Kamuluddin

SPECIES

Canine

BREED

Siberian Husky

SEX

Neutered Male

AGE

8 Years 2 Months

WEIGHT

31.9 kg

INTERPRETED BY

Sebastian Schaub, DVM
Dr. med. vet. DipECVDI

IMAGING PERFORMED BY

Lisa S.

HOSPITAL NAME

ASC Oceanside

REFERRING VET

Dr. Jennifer Short

INVOICE

36221

DATE

3/13/26

PRESENTING CLINICAL SIGNS

- Soft, nonpainful, cranial abdominal organomegaly palpable.
- Hepatic mass- open pending histopathology

COMPUTED TOMOGRAPHIC STUDY OF THE THORAX AND ABDOMEN

A high resolution pre- and post-contrast CT study of the thorax and abdomen is provided for review.

COMPUTED TOMOGRAPHIC FINDINGS

Thorax

In the subcutaneous tissue along the left thoracic wall, a well-defined, lipoma with small ill-defined, irregular soft tissue attenuating nodules is appreciated.

The space between the 5th and 6th sternebra is collapsed and the respective endplates present irregular margins and sclerosis with interspersed vacuum phenomenon.

The sternal, cranial mediastinal and tracheobronchial lymph nodes are small elongated with a normal short-to-long-axis-ratio is < 0.5, the attenuation and contrast enhancement pattern is uniform and considered within normal limits.

The cardiovascular structures including the pulmonary vasculature are within normal limits.

The bronchial tree presents with regular branching and tapers uniformly towards the periphery as expected, the bronchial walls are thin and smooth. The bronchus-to-artery ratio is within normal limits.

The lung parenchyma presents the expected architecture and attenuation behavior.

Small incidental gas pockets are seen within the esophageal lumen; there is no evidence of abnormal dilation.

Abdomen

The serosal fat presents normal attenuation behavior. There is no evidence of peritoneal effusion or peritonitis.

Both kidneys present within normal limits for size, shape and organ architecture. After contrast administration a bilaterally symmetric and uniform nephro- and pyelogram is noted.

The adrenal glands are within normal limits for size, shape and organ architecture.

The spleen presents with normal shape, even surface, uniformly attenuating parenchyma and homogeneous contrast enhancement, unremarkable.

Protruding from the caudal surface of the left division of the liver, an irregular ovoid shaped, uniform soft tissue attenuating and irregular contrast enhancing mass is seen, measuring 14.7 x 9.9 x 14.6 cm. The left divisional hepatic mass is protruding caudally into the peritoneal cavity; the stomach is deviated to the left and the pylorus caudally by the mass effect.



PATIENT

Logan Kamaluddin

SPECIES

Canine

BREED

Siberian Husky

SEX

Neutered Male

AGE

8 Years 2 Months

WEIGHT

31.9 kg

INTERPRETED BY

Sebastian Schaub, DVM
Dr. med. vet. DipECVDI

IMAGING PERFORMED BY

Lisa S.

HOSPITAL NAME

ASC Oceanside

REFERRING VET

Dr. Jennifer Short

INVOICE

36221

DATE

3/13/26

The position, delineation, wall and content of the gastrointestinal tract are considered within normal limits throughout.

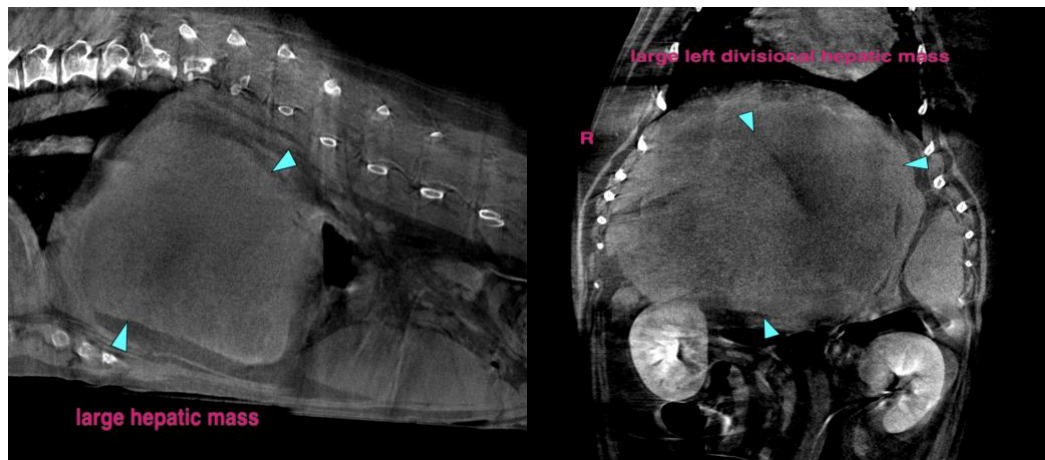
The bony and surrounding soft tissue structures reveal no abnormalities.

COMPUTED TOMOGRAPHIC DIAGNOSIS

- Large left divisional hepatic soft tissue mass
- Chronic degenerative changes of the cartilage between the 5th and 6th sternebra with secondary osseous remodeling of the respective sternebra
- Normal thorax, no evidence of pulmonary metastatic disease

INTERPRETATION OF THE FINDINGS & FURTHER RECOMMENDATIONS

The hepatic mass is consistent with primary hepatic neoplasia – such as hepatocellular adenoma or carcinoma formation. Complete surgical resection of the hepatic mass appears feasible.



The information and recommendations provided are based on the images presented by the referring veterinarian/sonographer. No evaluation can be communicated regarding pathology that was not visible in the image/video clips provided.

Thank you for this referral. If the clinical or image interpretation does not parallel your findings or if I can be of any further assistance please contact me.

Sebastian Schaub, DVM, Dr. med. vet. DipECVDI
info@sonopath.com