



PATIENT PRESENTING CLINICAL SIGNS

Tucker Leonard RF lameness for few days (has been noted on/off for past few months also after ball play but resolved quickly). No known trauma. On PE - grade 2 lameness of RF limb, mild-mod crepitus noted on R elbow joint and mild crepitus on L elbow and carpi bilat. 4dx neg in Jan. Consistently on flea/tick prevention and no ticks pulled off recently.

SPECIES

Canine

RADIOGRAPHIC STUDY OF THE RIGHT ELBOW JOINT

Radiographs of the right elbow joint in two orthogonal imaging planes.

BREED RADIOGRAPHIC FINDINGS

Lab

The periarticular bones of both elbow joint present moderate osteophyte new bone formation. At the medial aspect of the elbow joints, an isolated, fusiform shaped mineral opaque body is visible, superimposed on the flexor muscles. The tip of the contour of the medial coronoid process of the right elbow joint is ill-defined.

SEX

MN

RADIOGRAPHIC DIAGNOSIS

- Coronoid disease right elbow joint
- Moderate degenerative osteoarthritis elbow joints bilaterally
- Flexor enthesopathy elbow joints bilaterally with dystrophic mineralization

AGE

6 Years

INTERPRETATION OF THE FINDINGS & FURTHER RECOMMENDATIONS

INTERPRETED BY

Sebastian Schaub, DVM
Dr. med. vet. DipECVDI

The clinically appreciated lameness can be explained by the degenerative joint disease of the right elbow joint, very likely due to underlying disease of the medial coronoid process. The appreciated mineralized body at the medial aspect of the elbow joints is compatible with flexor enthesopathy with dystrophic mineralization – might be secondary to coronoid disease.

HOSPITAL NAME

Long Valley Animal
Hospital

Workup might be complemented by a CT study of the elbow joints ± arthroscopy/arthrotomy for revision of the elbow joint(s).

REFERRING VET

Dr. Stephanie Welch

INVOICE

57197

DATE

3-13-23



PATIENT

Tucker Leonard

SPECIES

Canine

BREED

Lab

SEX

MN

AGE

6 Years

INTERPRETED BY

Sebastian Schaub, DVM
Dr. med. vet. DipECVDI

HOSPITAL NAME

Long Valley Animal
Hospital

REFERRING VET

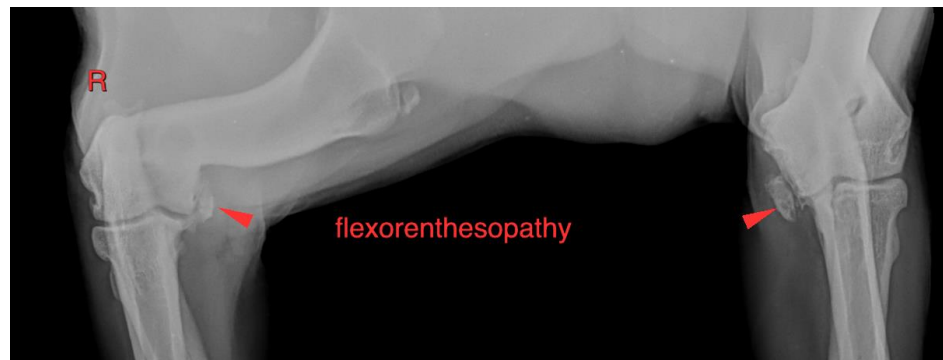
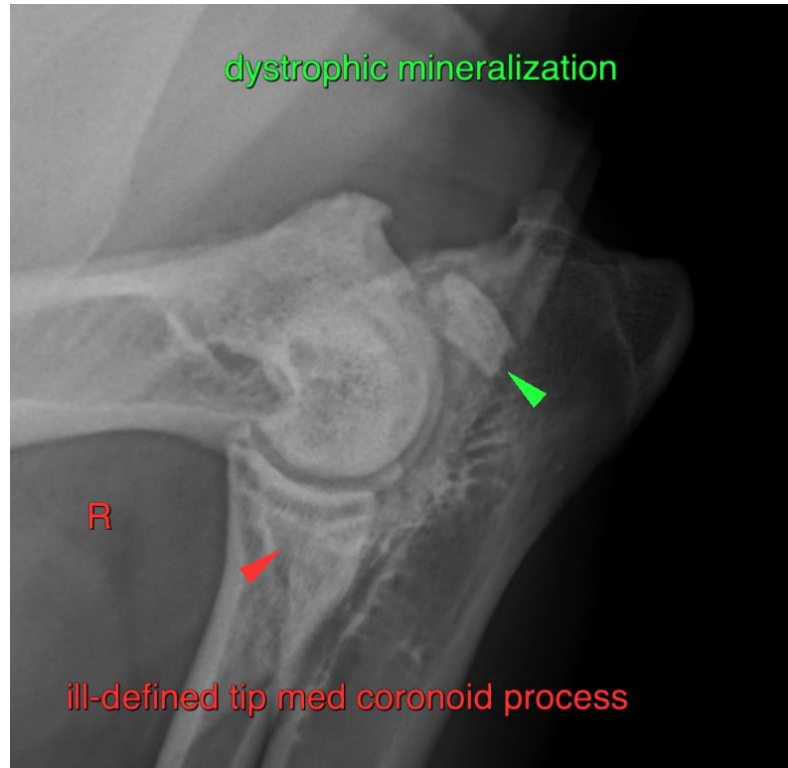
Dr. Stephanie Welch

INVOICE

57197

DATE

3-13-23





PATIENT

Tucker Leonard

The information and recommendations provided are based on the images presented by the referring veterinarian/sonographer. No evaluation can be communicated regarding pathology that was not visible in the image/video clips provided.

SPECIES

Canine

Thank you for this referral. If the clinical or image interpretation does not parallel your findings or if I can be of any further assistance please contact me.

Sebastian Schaub, Sebastian Schaub, DVM, Dr. med. vet. DipECVDI
sebast.schaub@gmail.com

BREED

Lab

SEX

MN

AGE

6 Years

INTERPRETED BY

Sebastian Schaub, DVM
Dr. med. vet. DipECVDI

HOSPITAL NAME

Long Valley Animal
Hospital

REFERRING VET

Dr. Stephanie Welch

INVOICE

57197

DATE

3-13-23