

**PATIENT PRESENTING CLINICAL SIGNS**

Chorri Murillo Hx of lameness of LH leg which has been there since Dec 2022. Responds well to NSAIDS
Abnormal PE/Chem/CBC/UA Results: Blood test results WNL Sedated rads done

SPECIES RADIOGRAPHIC STUDY OF THE PELVIS & STIFLE JOINTS

Canine A complete set of radiographs of the pelvis and the stifle joints is provided for review.

RADIOGRAPHIC FINDINGS**BREED**

Border Collie The osseous and surrounding soft tissue structures of the pelvis are within normal limits. The periarticular bones of the right coxofemoral joint present moderate osteophyte new bone formation – the right femoral head is misshapen. The right acetabular groove is shallow and the center of the right femoral head is lateral to the dorsal acetabular rim. The left coxofemoral joint has smooth osseous margins and a congruent joint space.

SEX

MN

The periarticular bones of the left stifle joint present mild to moderate osteophyte new bone formation and a moderate intracapsular soft tissue swelling of the right stifle joint is seen.

The periarticular bones of the right stifle joint are smooth and there is no sign for intracapsular soft tissue swelling.

AGE

5 Years

RADIOGRAPHIC DIAGNOSIS

- Degenerative osteoarthritis left stifle joint
- Articular swelling left stifle joint
- Advanced degenerative osteoarthritis right coxofemoral joint due to hip dysplasia
- Normal left coxofemoral joint
- Normal right stifle joint

INTERPRETED BY

Sebastian Schaub, DVM
Dr. med. vet. DipECVDI

HOSPITAL NAME

Balmy Beach Pet
Hospital

INTERPRETATION OF THE FINDINGS & FURTHER RECOMMENDATIONS

The radiographic study is consistent with chronic degenerative osteoarthritis with concomitant joint effusion of the left stifle joint. The most-likely underlying cause is (partial) rupture of the cranial cruciate ligament with or without meniscal disease.

REFERRING VET

Dr. Singh

A positive drawer sign or tibial compression test under general anesthesia can be used to confirm the diagnosis.

INVOICE

57203

DATE

3-13-23



PATIENT

Chorri Murillo

SPECIES

Canine

BREED

Border Collie

SEX

MN

AGE

5 Years

INTERPRETED BY

Sebastian Schaub, DVM
Dr. med. vet. DipECVDI

HOSPITAL NAME

Balmy Beach Pet
Hospital

REFERRING VET

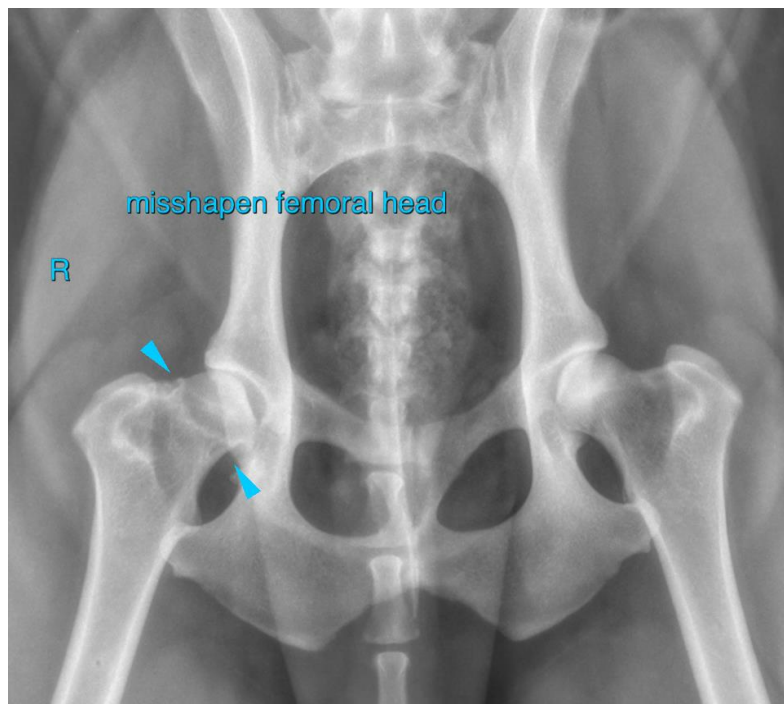
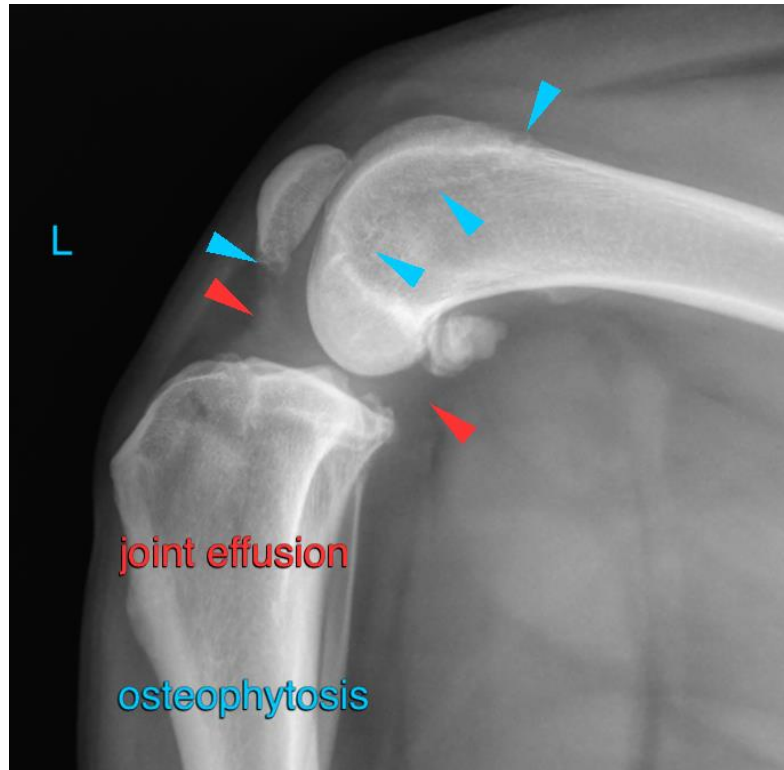
Dr. Singh

INVOICE

57203

DATE

3-13-23





PATIENT

Chorri Murillo

The information and recommendations provided are based on the images presented by the referring veterinarian/sonographer. No evaluation can be communicated regarding pathology that was not visible in the image/video clips provided.

SPECIES

Canine

Thank you for this referral. If the clinical or image interpretation does not parallel your findings or if I can be of any further assistance please contact me.

BREED

Border Collie

Sebastian Schaub, Sebastian Schaub, DVM, Dr. med. vet. DipECVDI
sebast.schaub@gmail.com

SEX

MN

AGE

5 Years

INTERPRETED BY

Sebastian Schaub, DVM
Dr. med. vet. DipECVDI

HOSPITAL NAME

Balmy Beach Pet
Hospital

REFERRING VET

Dr. Singh

INVOICE

57203

DATE

3-13-23