



PATIENT

Remi Wright

SPECIES

Canine

BREED

Boxer X Am. Bulldog

SEX

MN

AGE

5Y

WEIGHT

38.9kg

INTERPRETED BY

Sebastian Schaub, DVM
Dr. med. vet.
DipECVDD

IMAGING PERFORMED BY

VG, VH

HOSPITAL NAME

The Collegeway Animal
Hospital

REFERRING VET

Dr. Ehab Hanna

INVOICE

74184

DATE

3-12-26

PRESENTING CLINICAL SIGNS

- reluctant to jump/climb
- very stiff in neck area

RADIOGRAPHIC STUDY OF THE LUMBAR SPINE

Radiographs of the lumbar spine in two orthogonal image planes are provided for review.

RADIOGRAPHIC FINDINGS

The vertebral endplates L7/S1 present mild spondylosis formation.

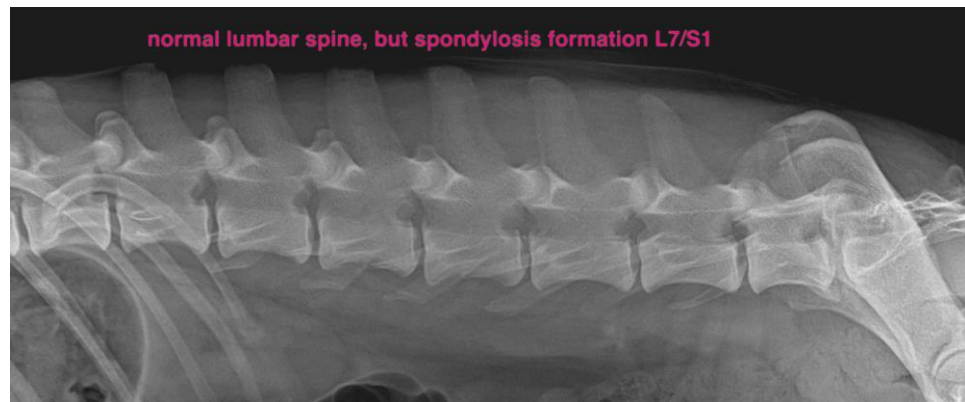
The remainder of the osseous and surrounding soft tissue structures of the lumbar spine are within normal limits; the intervertebral disc spaces present the expected width.

RADIOGRAPHIC DIAGNOSIS

- Mild spondylosis deformans L7/S1

INTERPRETATION OF THE FINDINGS & FURTHER RECOMMENDATIONS

The radiographic study reveals no abnormalities and an underlying cause for the presenting clinical signs cannot be specified. If there is strong suspicion for underlying myelopathy, workup can be complemented by a CT or MRI study of the spine.



The information and recommendations provided are based on the images presented by the referring veterinarian/sonographer. No evaluation can be communicated regarding pathology that was not visible in the image/video clips provided.

Thank you for this referral. If the clinical or image interpretation does not parallel your findings or if I can be of any further assistance please contact me.

Sebastian Schaub, Sebastian Schaub, DVM, Dr. med. vet. DipECVDD
info@sonopath.com