



PATIENT

Enzo Baez

SPECIES

Canine

BREED

Pitbull Mix

SEX

MN

AGE

4Y

WEIGHT

56lbs

INTERPRETED BY

Sebastian Schaub, DVM
Dr. med. vet.
DipECVDI

IMAGING PERFORMED BY

Dr. Carlos Abdul-Chani

HOSPITAL NAME

Byram Animal Hospital

REFERRING VET

Dr. Carlos Abdul-Chani

INVOICE

74167

DATE

3-12-26

PRESENTING CLINICAL SIGNS

- X-ray L pelvis limb lameness of one month duration
- 4dx Neg
- no response to NSAID
- Current meds: Carprofen 50mg BID

RADIOGRAPHIC STUDY OF THE STIFLE JOINTS

Radiographs of the stifle joints in two orthogonal image planes are provided for review.

RADIOGRAPHIC FINDINGS

The volume of the soft tissue shadow of the musculature of the left hind limb is moderately decreased.

The periarticular bones of the right stifle joint present smooth margins and there is no evidence of an intracapsular soft tissue swelling.

The periarticular bones of the left stifle joint present mild osteophyte new bone formation. The left stifle joint presents a mild increased volume of the intracapsular soft tissue shadow.

RADIOGRAPHIC DIAGNOSIS

- Mild osteoarthritis left stifle joint
- Mild articular swelling left stifle joint
- Disuse atrophy musculature left hind limb

INTERPRETATION OF THE FINDINGS & FURTHER RECOMMENDATIONS

The mild degenerative joint disease along with the mild effusion of the left stifle joint is suggestive for pathology of the cranial cruciate ligament ± meniscal disease. A positive drawer sign or tibial compression test under general anesthesia will support the diagnosis – partial rupture of the cranial cruciate ligament and potential thickening of the synovial capsule can result in only mild instability.



PATIENT

Enzo Baez

SPECIES

Canine

BREED

Pitbull Mix

SEX

MN

AGE

4Y

WEIGHT

56lbs

INTERPRETED BY

Sebastian Schaub, DVM
Dr. med. vet.
DipECVDI

IMAGING PERFORMED BY

Dr. Carlos Abdul-Chani

HOSPITAL NAME

Byram Animal Hospital

REFERRING VET

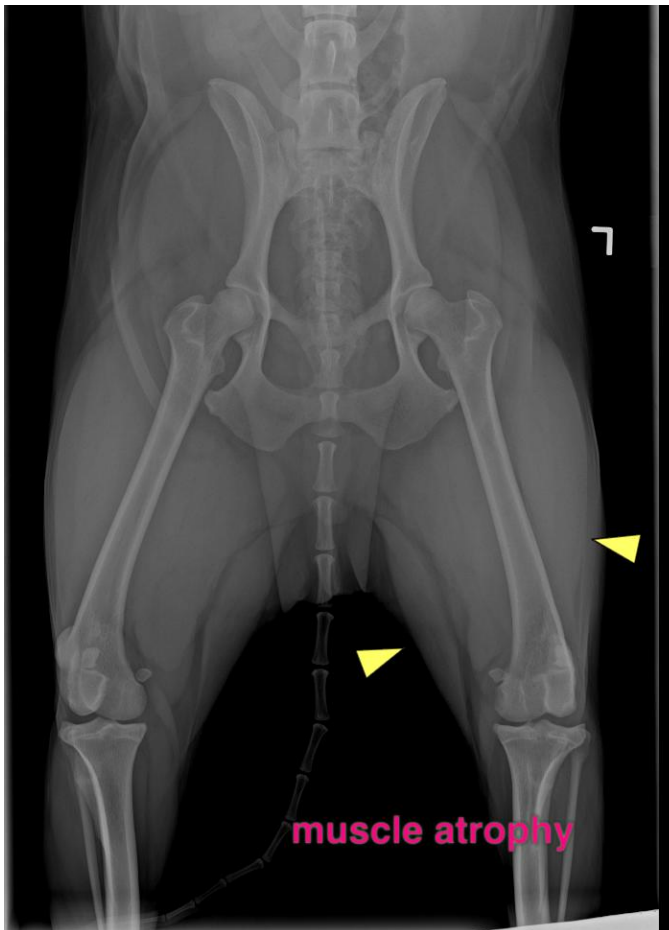
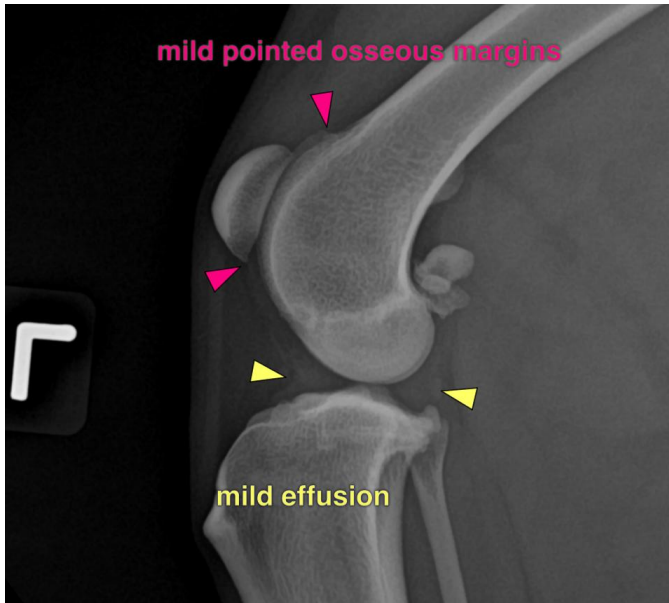
Dr. Carlos Abdul-Chani

INVOICE

74167

DATE

3-12-26





PATIENT

Enzo Baez

SPECIES

Canine

BREED

Pitbull Mix

SEX

MN

AGE

4Y

WEIGHT

56lbs

INTERPRETED BY

Sebastian Schaub, DVM
Dr. med. vet.
DipECVDI

**IMAGING
PERFORMED BY**

Dr. Carlos Abdul-Chani

HOSPITAL NAME

Byram Animal Hospital

REFERRING VET

Dr. Carlos Abdul-Chani

INVOICE

74167

DATE

3-12-26

The information and recommendations provided are based on the images presented by the referring veterinarian/sonographer. No evaluation can be communicated regarding pathology that was not visible in the image/video clips provided.

Thank you for this referral. If the clinical or image interpretation does not parallel your findings or if I can be of any further assistance please contact me.

Sebastian Schaub, Sebastian Schaub, DVM, Dr. med. vet. DipECVDI
info@sonopath.com