



PATIENT PRESENTING CLINICAL SIGNS

Dema Gates Historical mammary carcinoma and pyometra dx fall 2021. Surgical intervention followed by Piroxicam since that time and doing well. Recent note of hemorrhage from the urogenital tract and on ultrasound a mass was appreciated dorsal to the urinary bladder not consistent with bladder or urethra. CT pursued to assess point of origin and potential for surgical excision.

SPECIES

Canine COMPUTED TOMOGRAPHY OF THE ABDOMEN

A high resolution pre- and post-contrast CT study of the abdomen is provided for review.

BREED COMPUTED TOMOGRAPHIC FINDINGS

Husky Mix The serosal fat presents normal attenuation behavior. There is no evidence of peritoneal effusion or peritonitis.

SEX

Female Spayed

Both kidneys present within normal limits for size, shape and organ architecture. A small amount of mineral attenuating material is associated with the renal pelvis bilaterally. After contrast administration a bilaterally symmetric and uniform nephro- and pyelogram is noted. The urinary bladder is mild to moderately filled with urine. Between the rectum and the urinary bladder, originating from the uterine stump, a well-defined, uniform soft tissue attenuating and mild irregular contrast enhancing ovoid shaped mass is seen, measuring 3.6 x 3.0 x 5.2 cm in size.

AGE

10

At the caudolateral aspect of the left kidney, a small (<5mm), soft tissue attenuating nodule is seen as well as a prominent left ovarian vein.

INTERPRETED BY

The adrenal glands are within normal limits for size, shape and organ architecture.

Sebastian Schaub, DVM
Dr. med. vet. DipECVDI

Both liver and spleen present with normal shape, even surface, uniformly attenuating parenchyma and homogeneous contrast enhancement, unremarkable.

The pancreas is evenly contoured, the pancreatic parenchyma is homogeneous and presents uniform contrast enhancement.

HOSPITAL NAME

Southern Oregon
Veterinary Specialty
Center

The position, delineation, wall and content of the gastrointestinal tract are considered within normal limits throughout.

The bony and surrounding soft tissue structures reveal no abnormalities.

COMPUTED TOMOGRAPHIC DIAGNOSIS

REFERRING VET

Rory Applegate

- Soft tissue mass uterine stump
- Suspect left sided small ovarian remnant
- Nephrolithiasis without signs of mechanical obstruction

INVOICE INTERPRETATION OF THE FINDINGS & FURTHER RECOMMENDATIONS

57187

The mass originating from the uterine stump is concerning for neoplastic transformation – such as leiomyoma, leiomyosarcoma, carcinoma. The small nodular lesion appreciated in the region of the left ovary is highly suggestive for small ovarian remnant – the diagnosis is supported by the prominent left ovarian vein and visible left ovarian artery. A differential for the small nodular in the region of the left ovary is granuloma following ovariectomy. Persistent sexual steroids might be a trigger for accompanying stump pyometra. Surgical excision of the uterine mass is feasible and should be complemented by excision of the suspected ovarian remnant.

DATE

3-12-23



PATIENT

Dema Gates

SPECIES

Canine

BREED

Husky Mix

SEX

Female Spayed

AGE

10

INTERPRETED BY

Sebastian Schaub, DVM
Dr. med. vet. DipECVDI

HOSPITAL NAME

Southern Oregon
Veterinary Specialty
Center

REFERRING VET

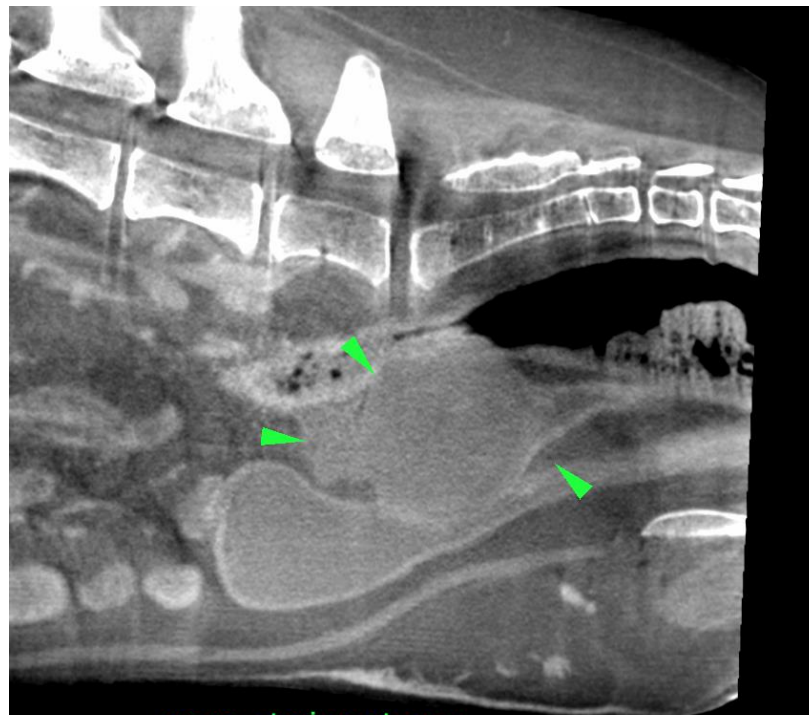
Rory Applegate

INVOICE

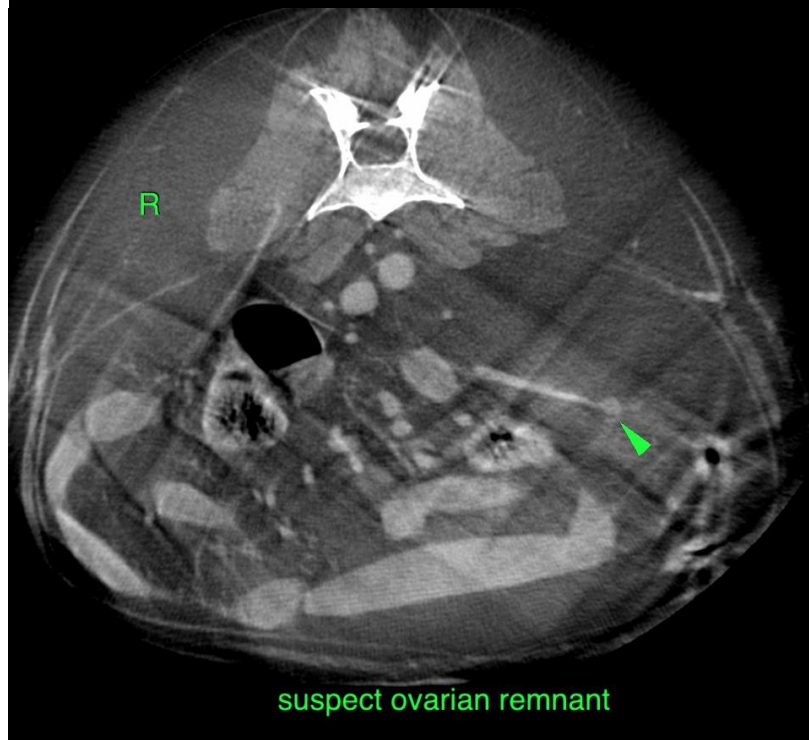
57187

DATE

3-12-23



mass uterine stump



suspect ovarian remnant



PATIENT

Dema Gates

SPECIES

Canine

BREED

Husky Mix

SEX

Female Spayed

AGE

10

INTERPRETED BY

Sebastian Schaub, DVM
Dr. med. vet. DipECVDI

HOSPITAL NAME

Southern Oregon
Veterinary Specialty
Center

REFERRING VET

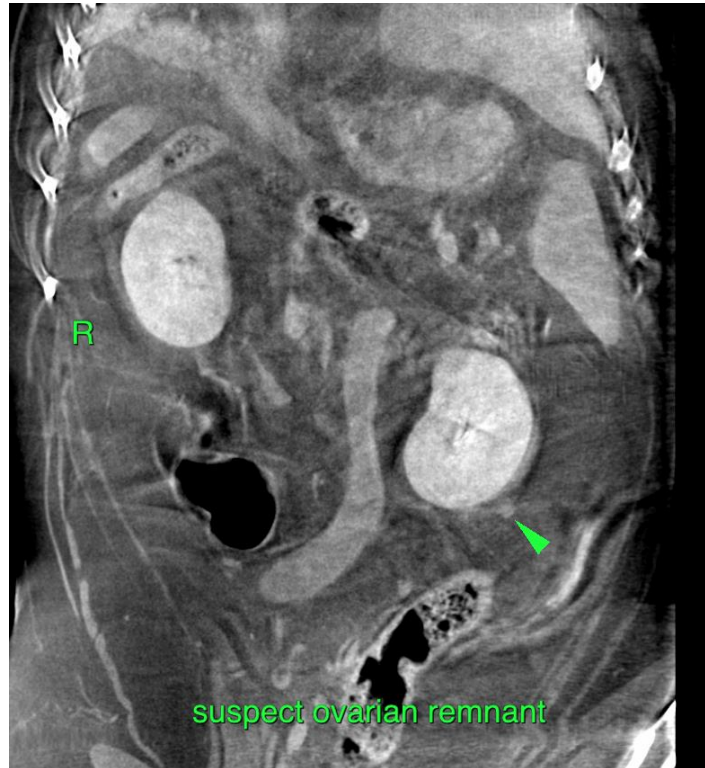
Rory Applegate

INVOICE

57187

DATE

3-12-23



The information and recommendations provided are based on the images presented by the referring veterinarian/sonographer. No evaluation can be communicated regarding pathology that was not visible in the image/video clips provided.

Thank you for this referral. If the clinical or image interpretation does not parallel your findings or if I can be of any further assistance please contact me.

Sebastian Schaub, Sebastian Schaub, DVM, Dr. med. vet. DipECVDI
sebast.schaub@gmail.com