



PATIENT

Roger Stoddard

PRESENTING CLINICAL SIGNS

sudden onset of pain and discomfort neck pain when head turned to the right side
Abnormal PE/Chem/CBC/UA Results: Normal labs

SPECIES

Canine

RADIOGRAPHIC STUDY OF THE NECK

Radiographs of the neck in two orthogonal imaging planes are provided for review.

BREED

Cocker Spaniel

RADIOGRAPHIC FINDINGS

The lateral projections of the neck are moderately rotated.

SEX

MN

The osseous and soft tissue structures of the neck are within normal limits.

AGE

13 Years

RADIOGRAPHIC DIAGNOSIS

- Suspect chondroid disc degeneration C4/C5 versus superimposed transverse process/facet joint

INTERPRETATION OF THE FINDINGS & FURTHER RECOMMENDATIONS

The radiographic study of the cervical spine presents no abnormality, explaining the acute onset of pain. If clinical signs are refractory to empirical therapy by pain management & rest or deteriorate, cross-sectional imaging is recommended for further definition.

TECHNICAL COMMENTS

There is moderate rotation of the cervical spine, limiting the diagnostic value and assessment of the intervertebral disc spaces.

INTERPRETED BY

Sebastian Schaub, DVM
Dr. med. vet. DipECVDI

HOSPITAL NAME

Balmy Beach Pet
Hospital

REFERRING VET

Dr. Singh

INVOICE

50884

DATE

3-12-22



PATIENT

Roger Stoddard

SPECIES

Canine

BREED

Cocker Spaniel

SEX

MN

AGE

13 Years

INTERPRETED BY

Sebastian Schaub, DVM
Dr. med. vet. DipECVDI

HOSPITAL NAME

Balmy Beach Pet
Hospital

REFERRING VET

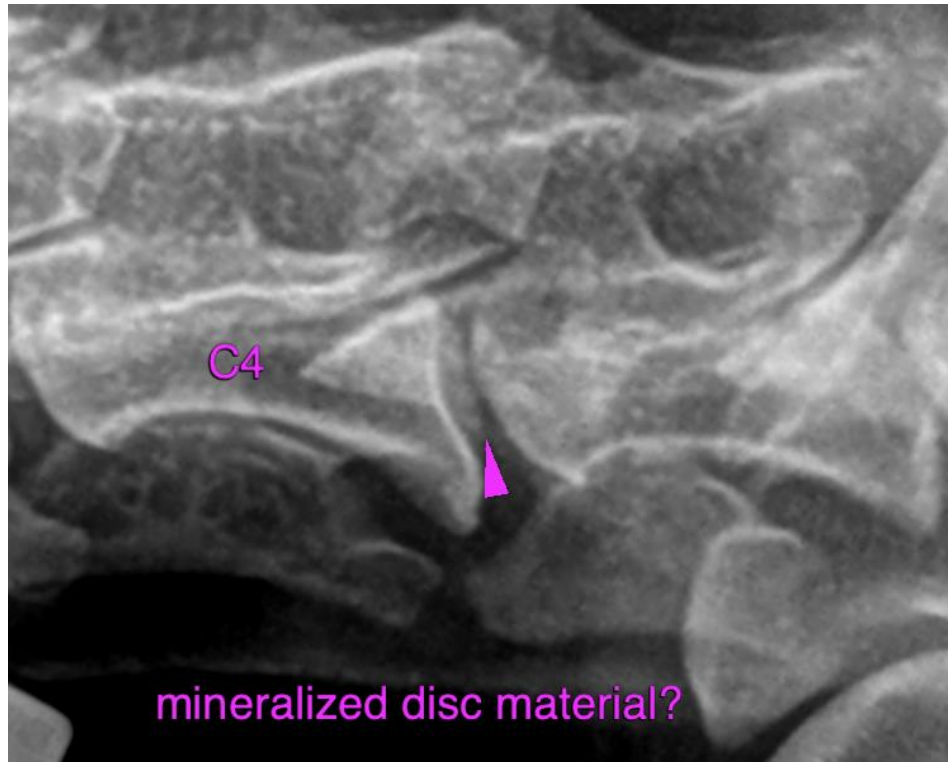
Dr. Singh

INVOICE

50884

DATE

3-12-22



The information and recommendations provided are based on the images presented by the referring veterinarian/sonographer. No evaluation can be communicated regarding pathology that was not visible in the image/video clips provided.

Thank you for this referral. If the clinical or image interpretation does not parallel your findings or if I can be of any further assistance please contact me.

Sebastian Schaub, Sebastian Schaub, DVM, Dr. med. vet. DipECVDI
sebast.schaub@gmail.com