



PATIENT

Sam Piper

SPECIES

Feline

BREED

DSH

SEX

MN

AGE

20Y

WEIGHT

11.5lbs

INTERPRETED BY

Sebastian Schaub, DVM
Dr. med. vet.
DipECVDI

IMAGING PERFORMED BY

Veterinary Technicians

HOSPITAL NAME

Northshore Veterinary
Hospital

REFERRING VET

Caley Howard

INVOICE

74140

DATE

3-11-26

PRESENTING CLINICAL SIGNS

- Long history of intermittent RH lameness. Fell earlier today and now has a 2/4 RH lameness. Sore on caudal lumbar palpation, just cranial to the point of the hips. Has decent hip extension. Good neuro exam. Significant muscle wasting

Abnormal PE/Chem/CBC/UA Results: Chronic CKD 3/6 systolic murmur **Owner was hesitant for us to pull on his limbs for good views today, we did our best

RADIOGRAPHIC STUDY OF THE LUMBAR SPINE

Radiographs of the lumbar spine in two orthogonal image planes are provided for review.

RADIOGRAPHIC FINDINGS

The osseous and surrounding soft tissue structures of the lumbar spine are within normal limits. The intervertebral disc spaces present an even width.

In the pictured parts of the thorax, in the ventral aspect of the caudal part of the left cranial lung lobe, a well-defined, ovoid shaped, uniform soft tissue opaque mass is seen; measuring up to two intercostal spaces in length.

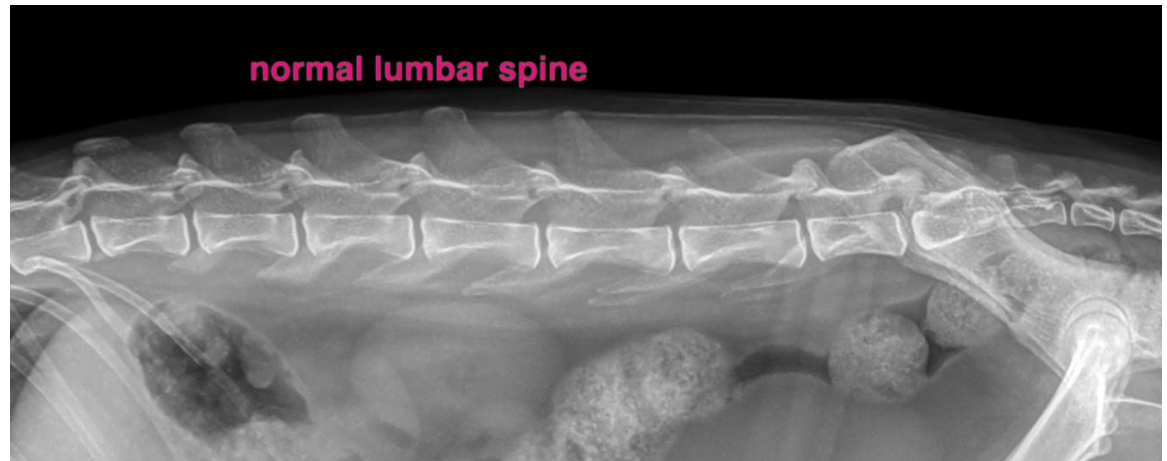
RADIOGRAPHIC DIAGNOSIS

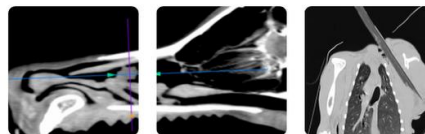
- Solitary pulmonary mass – likely in the ventral aspect of the caudal part of the left cranial lung lobe
- Normal lumbar spine

INTERPRETATION OF THE FINDINGS & FURTHER RECOMMENDATIONS

The radiographic study of the lumbar spine reveals no abnormalities.

The solitary pulmonary mass can present primary pulmonary soft tissue neoplasia, granuloma or zone with pyogranulomatous pneumonia. Ultrasound guided FNA sampling can be performed for specification.





PATIENT

Sam Piper

SPECIES

Feline

BREED

DSH

SEX

MN

AGE

20Y

WEIGHT

11.5lbs

INTERPRETED BY

Sebastian Schaub, DVM
Dr. med. vet.
DipECVDI

IMAGING PERFORMED BY

Veterinary Technicians

HOSPITAL NAME

Northshore Veterinary
Hospital

REFERRING VET

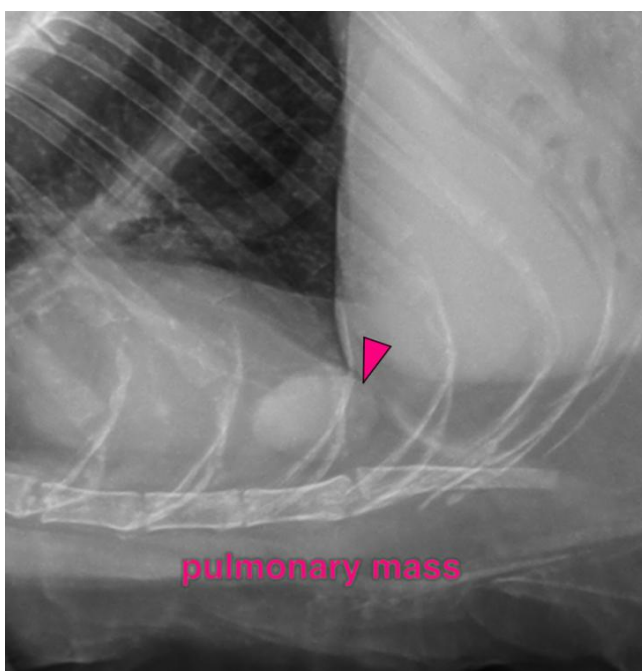
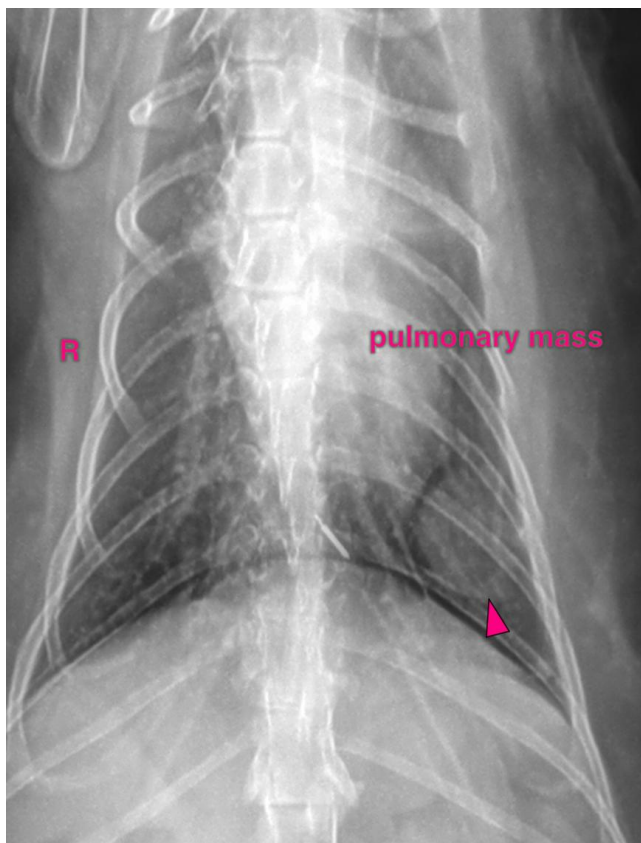
Caley Howard

INVOICE

74140

DATE

3-11-26





PATIENT

Sam Piper

SPECIES

Feline

BREED

DSH

SEX

MN

AGE

20Y

WEIGHT

11.5lbs

INTERPRETED BY

Sebastian Schaub, DVM
Dr. med. vet.
DipECVDI

IMAGING PERFORMED BY

Veterinary Technicians

HOSPITAL NAME

Northshore Veterinary
Hospital

REFERRING VET

Caley Howard

INVOICE

74140

DATE

3-11-26

The information and recommendations provided are based on the images presented by the referring veterinarian/sonographer. No evaluation can be communicated regarding pathology that was not visible in the image/video clips provided.

Thank you for this referral. If the clinical or image interpretation does not parallel your findings or if I can be of any further assistance please contact me.

Sebastian Schaub, Sebastian Schaub, DVM, Dr. med. vet. DipECVDI
info@sonopath.com