



PATIENT PRESENTING CLINICAL SIGNS

Magnus Gannon History: Owner noticed a hard lump in P's inguinal area. Both sides. Left side was more obvious to see. Behavior otherwise is normal, and Magnus is BAR. Based on history nothing is significant. Based on physical exam hard lump on both sides of the inguinal area. Cat is overweight.

SPECIES RADIOGRAPHIC STUDY OF THE ABDOMEN

Feline Radiographs of the abdomen in three imaging planes are provided for review.

BREED RADIOGRAPHIC FINDINGS

DSH Tabby The surrounding bony structures are within normal limits.

SEX

Neutered Male No abnormalities of the extraabdominal soft tissues are noted. The abdominal wall is smooth and thin. The serosal detail is maintained throughout the peritoneal and retroperitoneal space. The liver is appropriate in position, size and presents uniform opacity.

AGE

2 Years The splenic head is in the anticipated position and within normal limits for size and opacity. Both kidneys are seen and present with normal size, shape, delineation and opacity. The urinary bladder is in its anticipated position. No radiopaque calculi are noted throughout the upper and lower urinary tract.

INTERPRETED BY

Sebastian Schaub,
DVM Dr. med. vet.
DipECVDI

The stomach is in its anticipated position and presents normal content. The small intestinal loops are of even diameter and non-dilated, a small amount of gas is seen within the small intestinal loops and considered within normal limits.

HOSPITAL NAME

Wilsn Road VH

The colon is seen in the expected position and presents with appropriate content.

RADIOGRAPHIC DIAGNOSIS

- Normal abdomen

REFERRING VET

Dr. Malek

INTERPRETATION OF THE FINDINGS & FURTHER RECOMMENDATIONS

The radiographic study of the abdomen presents no abnormalities. No abnormalities in the inguinal region are appreciated, but subcutaneous fat-depots.

INVOICE

21594

DATE

3/11/23



PATIENT

Magnus Gannon

SPECIES

Feline

BREED

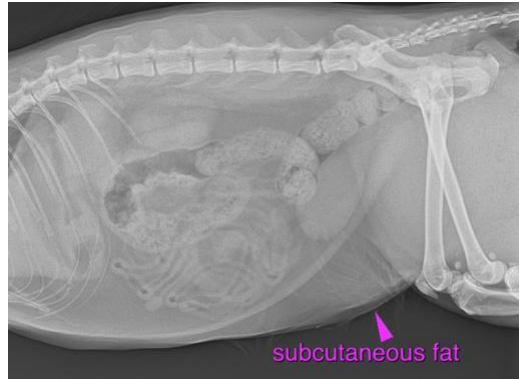
DSH Tabby

SEX

Neutered Male

AGE

2 Years



The information and recommendations provided are based on the images presented by the referring veterinarian/sonographer. No evaluation can be communicated regarding pathology that was not visible in the image/video clips provided.

Thank you for this referral. If the clinical or image interpretation does not parallel your findings or if I can be of any further assistance please contact me.

Sebastian Schaub, Sebastian Schaub, DVM, Dr. med. vet. DipECVDI
sebast.schaub@gmail.com

INTERPRETED BY

Sebastian Schaub,
DVM Dr. med. vet.
DipECVDI

HOSPITAL NAME

Wilsn Road VH

REFERRING VET

Dr. Malek

INVOICE

21594

DATE

3/11/23