



PATIENT PRESENTING CLINICAL SIGNS

Aria Saunders History: Aria is a 3 year old intact female American Bull Dog Mix has a history of limping on her right hind leg over the last week. She has history of luxating patella on her right hind leg over the last 2 years. On the exam: BAR HP. limping on her right hind leg. Occasionally not able to support any weight on the right hind leg. Luxating patella on her right hind. Positive drawer test on right hind leg. Overextension of right hind leg was painful.

SPECIES

Canine

RADIOGRAPHIC STUDY OF THE PELVIS & STIFLE JOINTS

BREED

A complete set of radiographs of the pelvis and the stifle joints is provided for review.

American Bulldog Mix

RADIOGRAPHIC FINDINGS

SEX

Female

The osseous and surrounding soft tissue structures of the pelvis are within normal limits. The periarticular bones of both coxofemoral joints present advanced osteophyte new bone formation and the femoral heads are misshapen. The acetabular groove bilaterally is shallow and the center of the femoral heads is lateral to the dorsal acetabular rim. The joint space of the coxofemoral joints is incongruent.

AGE

3 Years

The patella of both stifle joints is superimposed on the medial femoral condyle. The periarticular bones of the right stifle joint present mild osteophyte new bone formation. Both stifle joints present a mild intracapsular soft tissue swelling, R>L.

INTERPRETED BY

Sebastian Schaub,
DVM Dr. med. vet.
DipECVDI

RADIOGRAPHIC DIAGNOSIS

- Mild degenerative osteoarthritis right stifle joint
- Mild articular swelling stifle joints bilaterally, R>L
- Bilateral medial patellar luxation
- Advanced degenerative osteoarthritis coxofemoral joints bilaterally due to hip dysplasia

HOSPITAL NAME

Beaches-Fallingbrook
VC

INTERPRETATION OF THE FINDINGS & FURTHER RECOMMENDATIONS

The mild degenerative osteoarthritis and joint effusion of the right stifle joint might be a sequela to the patellar luxation, however pathology of the cranial cruciate ligament ± meniscal pathology are more likely due to the recent onset of clinical signs. The diagnosis is supported by the clinically appreciated positive drawer test.

REFERRING VET

Dr. Shahsavari

INVOICE

21595

DATE

3/11/23



PATIENT

Aria Saunders

SPECIES

Canine

BREED

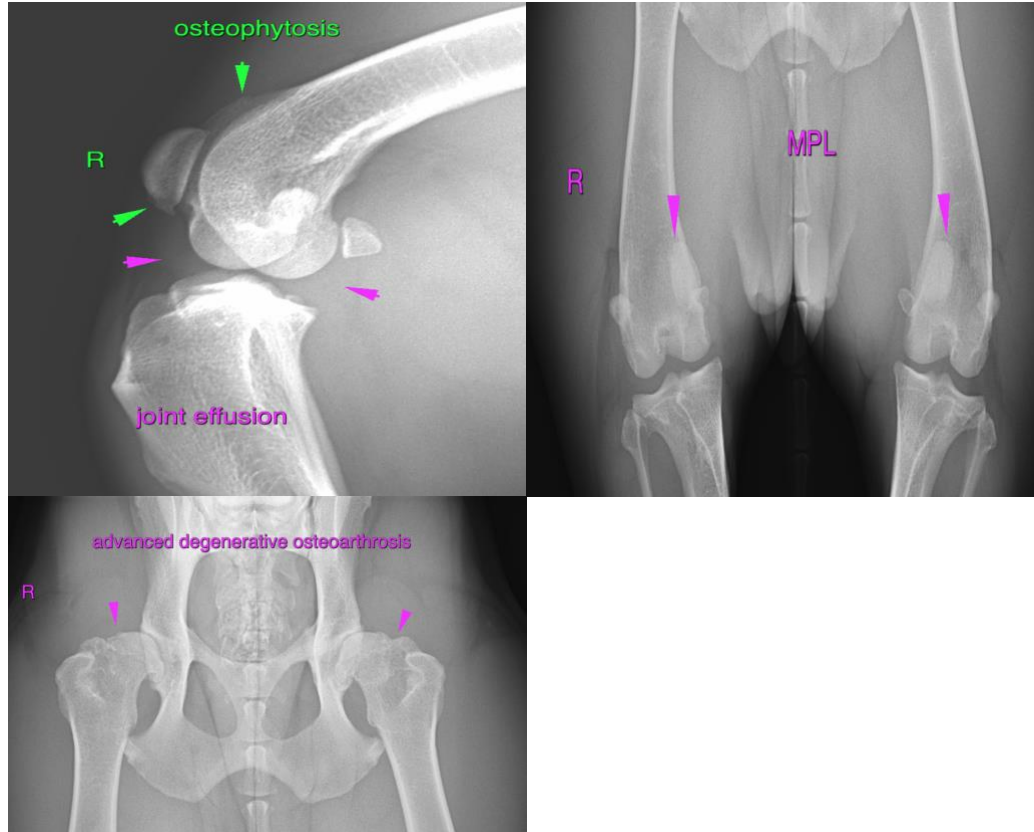
American Bulldog Mix

SEX

Female

AGE

3 Years



INTERPRETED BY

Sebastian Schaub,
DVM Dr. med. vet.
DipECVDI

The information and recommendations provided are based on the images presented by the referring veterinarian/sonographer. No evaluation can be communicated regarding pathology that was not visible in the image/video clips provided.

HOSPITAL NAME

Beaches-Fallingbrook
VC

Thank you for this referral. If the clinical or image interpretation does not parallel your findings or if I can be of any further assistance please contact me.

Sebastian Schaub, Sebastian Schaub, DVM, Dr. med. vet. DipECVDI
sebast.schaub@gmail.com

REFERRING VET

Dr. Shavsavari

INVOICE

21595

DATE

3/11/23