



PATIENT

Shadow Michaud

PRESENTING CLINICAL SIGNS

Vomiting for 6 days , not eating lethargic
Abnormal PE/Chem/CBC/UA Results: High BUN /Phos & bilirubin Pancreatitis

SPECIES

Feline

RADIOGRAPHIC STUDY OF THE THORAX & ABDOMEN

An overview study including the thorax and abdomen in three imaging planes are provided for review.

BREED

DMH

RADIOGRAPHIC FINDINGS

Thorax

The surrounding bony structures are within normal limits.

SEX

Spayed Female

The extrathoracic soft tissues present homogeneous without abnormalities.

The heart is of normal size and shape, there is no evidence of cardiac chamber or vascular enlargement. The pulmonary vasculature is within normal limits.

AGE

16 Months

The trachea is normal in diameter and presents the anticipated course. The luminal outline of the trachea is smooth.

INTERPRETED BY

Sebastian Schaub, DVM
Dr. med. vet. DipECVDI

The bronchial tree presents with thin walls and tapers uniformly towards the periphery as expected.

The lung parenchyma presents the expected architecture and opacity; the intrapulmonary vascular branching is seen up to the third order lung vessels.

HOSPITAL NAME

St. Catherine's Animal
Hospital

The diaphragm is well delineated with even surface and the expected mild cranial bulging of the diaphragmatic cupola.

Abdomen

The surrounding bony structures are within normal limits.

REFERRING VET

Dr. Mena

No abnormalities of the extraabdominal soft tissues are noted. The abdominal wall is smooth and thin.

The liver is appropriate in position, size and presents uniform opacity.

INVOICE

50857

The splenic head is in the anticipated position and within normal limits for size and opacity. The splenic body and tail are considered normal for position, size, shape and opacity.

DATE

3-10-22

Both kidneys are seen and present with normal size, shape, delineation and opacity. The urinary bladder is in its anticipated position. No radiopaque calculi are noted throughout the upper and lower urinary tract.

The stomach is in its anticipated position and presents normal content.



PATIENT

Shadow Michaud

There is a radiopaque linear structured visible in a small intestinal segment. Crowding and plication of the respective small intestinal segment, containing the linear radiopaque foreign structure, is seen with atypical triangular shaped intraluminal gas bubbles. The duodenum is moderately distended by gas. The serosal fat level with the plicates small intestinal segments presents focal moderate fat-stranding and nearly gas opaque small zones.

SPECIES

Feline

The colon is seen in the expected position and presents with appropriate content.

RADIOGRAPHIC DIAGNOSIS

BREED

DMH

- Linear small intestinal foreign body with mechanical obstruction
- Localized (septic) peritonitis
- Normal thorax

INTERPRETATION OF THE FINDINGS & FURTHER RECOMMENDATIONS

SEX

Spayed Female

The radiographic study is consistent with a linear small intestinal foreign body with secondary mechanical obstruction and signs for local peritonitis with possible small amount of free gas, concerning laceration of the intestinal tract by the linear foreign body. Surgical intervention is indicated. Check the base of the tongue as well!

AGE

16 Months

INTERPRETED BY

Sebastian Schaub, DVM
Dr. med. vet. DipECVDI

HOSPITAL NAME

St. Catherine's Animal
Hospital

REFERRING VET

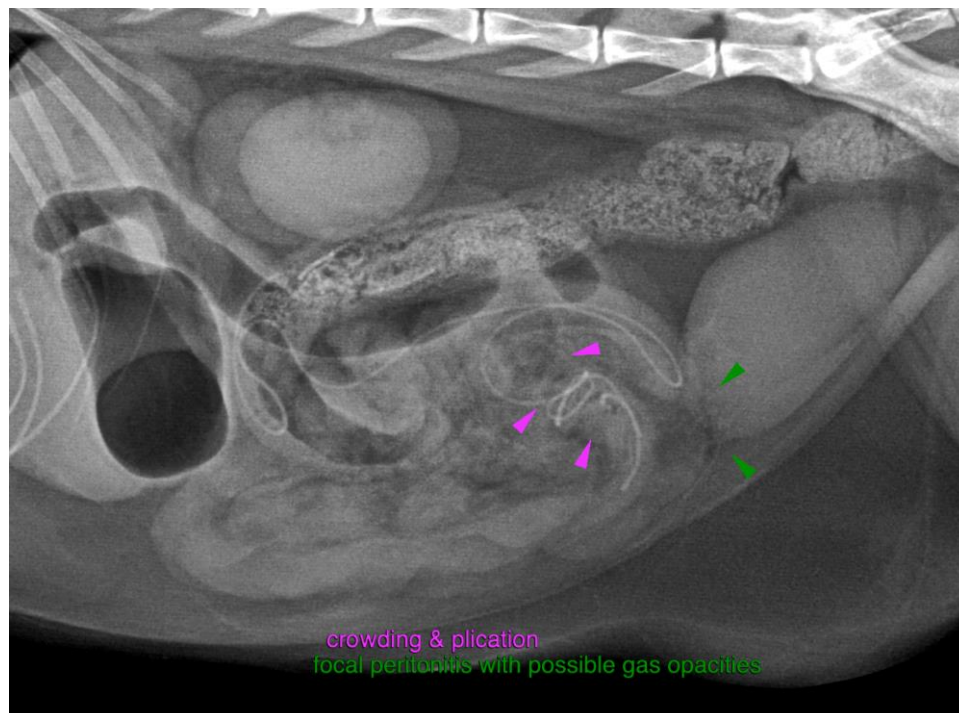
Dr. Mena

INVOICE

50857

DATE

3-10-22



crowding & plication
focal peritonitis with possible gas opacities



PATIENT

Shadow Michaud

SPECIES

Feline

BREED

DMH

SEX

Spayed Female

AGE

16 Months

INTERPRETED BY

Sebastian Schaub, DVM
Dr. med. vet. DipECVDI

HOSPITAL NAME

St. Catherine's Animal
Hospital

REFERRING VET

Dr. Mena

INVOICE

50857

DATE

3-10-22

The information and recommendations provided are based on the images presented by the referring veterinarian/sonographer. No evaluation can be communicated regarding pathology that was not visible in the image/video clips provided.

Thank you for this referral. If the clinical or image interpretation does not parallel your findings or if I can be of any further assistance please contact me.

Sebastian Schaub, Sebastian Schaub, DVM, Dr. med. vet. DipECVDI
sebast.schaub@gmail.com