



**PATIENT PRESENTING CLINICAL SIGNS**

Del Alamo Exophthalmos OS, large mass left side of face

**COMPUTED TOMOGRAPHY OF THE SKULL & THORAX**

**SPECIES**

Feline

A high resolution pre- and post-contrast CT study of the skull and a post-contrast CT study of the thorax are provided for review.

**COMPUTED TOMOGRAPHIC FINDINGS**

**BREED**

DSH

Skull

Multiple teeth are absent. Originating from the left ramus of the mandible, an expansile, amorphous mineralizing mass is seen with advanced complete loss of the normal architecture of the ramus of the mandible. The left condylar process of the mandible is maintained. Pressure erosion of the left zygomatic arch level with the mandibular mass is seen. The mass of the left ramus of the mandible is measuring 2.9 x 4.2 x 3.7 cm in size. Post contrast administration the left mandibular mass is heterogeneous moderately contrast enhancing. The left ocular bulb is displaced rostrally and dorsally by the mass effect.

**AGE**

9 Years

The nasal cavity presents the expected aerated spaces between thin & even conchae and turbinates with smooth mucosal lining.

Both temporomandibular joints present congruent joint spaces with even subchondral bone surfaces and are considered within normal limits.

**INTERPRETED BY**

Sebastian Schaub, DVM  
Dr. med. vet. DipECVDI

Both tympanic bullae are aerated, the mucosal lining is not seen, the bony wall is smooth and thin. The external ear canals are within normal limits.

**HOSPITAL NAME**

Mobile Pet Imaging

The brain presents no deviation from normal anatomy and symmetry. The brain parenchyma is homogeneous and within normal limits for attenuation and distribution of contrast enhancement. The ventricular system is non-dilated and symmetric.

The submandibular and medial retropharyngeal lymph nodes are small and elongated with a normal short-to-long-axis-ratio is < 0.5, the attenuation and contrast enhancement pattern is uniform.

**REFERRING VET**

Meaux

Thorax

The bony and surrounding soft tissue structures are within normal limits.

**INVOICE**

50872

The sternal, cranial mediastinal and tracheobronchial lymph nodes are small elongated with a normal short-to-long-axis-ratio is < 0.5, the attenuation and contrast enhancement pattern is uniform and considered within normal limits.

The cardiovascular structures including the pulmonary vasculature are within normal limits.

**DATE**

3-10-22

The bronchial tree presents with regular branching and tapers uniformly towards the periphery as expected, the bronchial walls are thin and smooth. The bronchus-to-artery ratio is within normal limits.



**PATIENT** The lung parenchyma presents the expected architecture and attenuation behavior.

Del Alamo Small incidental gas pockets are seen within the esophageal lumen, there is no evidence of abnormal dilation.

**SPECIES** **COMPUTED TOMOGRAPHIC DIAGNOSIS**

- Feline
- Monostotic expansile aggressive mixed osteoproliferative and osteolytic lesion left ramus of the mandible
  - Secondary pressure erosion of the left zygomatic arch level with the mass
- BREED**
- Secondary left sided exophthalmos
  - Multiple absent teeth
- DSH
- Structural normal thorax, no evidence of pulmonary metastatic disease

**INTERPRETATION OF THE FINDINGS & FURTHER RECOMMENDATIONS**

**SEX** The CT study is consistent with primary osseous neoplasia, originating from the left ramus of the mandible. Differentials include osteosarcoma, chondrosarcoma, fibrosarcoma, squamous cell carcinoma. FNA sampling can be used as advanced diagnostic tool. The chances of left sided caudal hemimandibulectomy might be discussed with surgeon & dentist, radiation therapy might be a consideration as well.

Neutered Male

**AGE**

9 Years

**INTERPRETED BY**

Sebastian Schaub, DVM  
Dr. med. vet. DipECVDI

**HOSPITAL NAME**

Mobile Pet Imaging

**REFERRING VET**

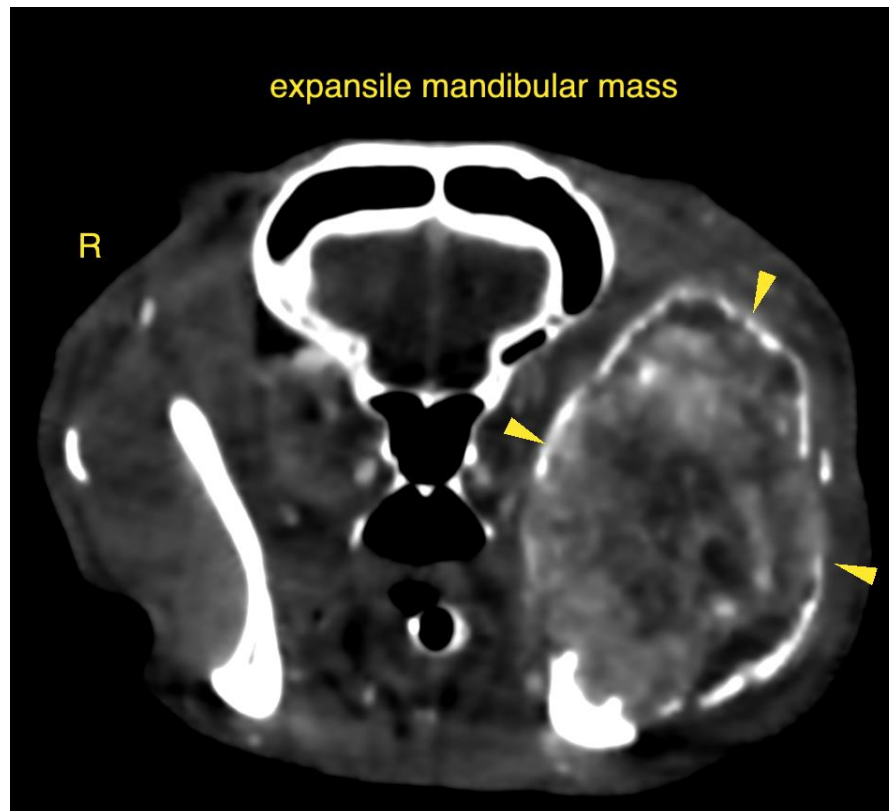
Meaux

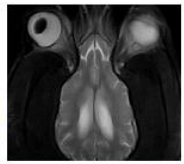
**INVOICE**

50872

**DATE**

3-10-22





**PATIENT**

Del Alamo

**SPECIES**

Feline

**BREED**

DSH

**SEX**

Neutered Male

**AGE**

9 Years

**INTERPRETED BY**

Sebastian Schaub, DVM  
Dr. med. vet. DipECVDI

**HOSPITAL NAME**

Mobile Pet Imaging

**REFERRING VET**

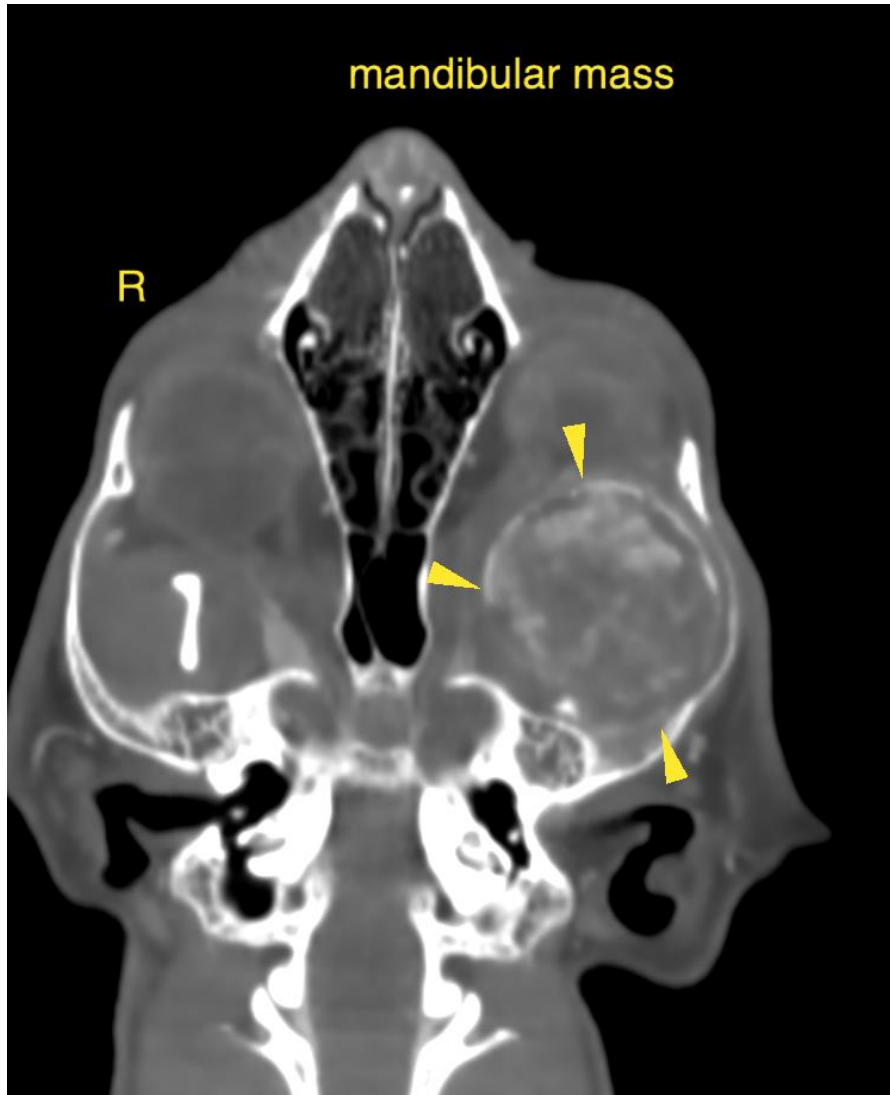
Meaux

**INVOICE**

50872

**DATE**

3-10-22



The information and recommendations provided are based on the images presented by the referring veterinarian/sonographer. No evaluation can be communicated regarding pathology that was not visible in the image/video clips provided.

Thank you for this referral. If the clinical or image interpretation does not parallel your findings or if I can be of any further assistance please contact me.

**Sebastian Schaub**, Sebastian Schaub, DVM, Dr. med. vet. DipECVDI  
sebast.schaub@gmail.com