



**PATIENT**

Punkin Martell

**PRESENTING CLINICAL SIGNS**

Intermittent forelimb lameness, difficult to localize to a leg. Occurs after exercise. Responds to NSAID. Never seen at time of exam.  
Abnormal PE/Chem/CBC/UA Results: Not performed

**SPECIES**

Canine

**RADIOGRAPHIC STUDY OF THE SHOULDER AND ELBOW JOINTS**

Radiographs of the shoulder and elbow joints in two orthogonal imaging planes are provided for review.

**BREED**

Australian Shepherd

**RADIOGRAPHIC FINDINGS**

Both shoulder joints present smooth osseous margins and the surrounding soft tissue structures are within normal limits.

**SEX**

FS

Both elbow joints present mild to moderate osteophyte new bone formation on the proximal aspect of the anconeal process. The contour of the medial coronoid process of the left elbow joint is ill-defined and the tip cannot be clearly delineated.

**AGE**

2 Years

**RADIOGRAPHIC DIAGNOSIS**

- Mild degenerative osteoarthritis elbow joints bilaterally
- Coronoid disease left elbow joint
- Suspect coronoid disease right elbow joint
- Normal shoulder joints

**INTERPRETED BY**

Sebastian Schaub, DVM  
Dr. med. vet. DipECVDI

**INTERPRETATION OF THE FINDINGS & FURTHER RECOMMENDATIONS**

There is evidence of bilateral degenerative joint disease of the elbow joints and underlying pathology of the medial coronoid process is considered very likely. A CT study can be used for further definition and potential surgical planning.

**HOSPITAL NAME**

Ruidoso Animal Clinic

**REFERRING VET**

Amanda Favis

**INVOICE**

50620

**DATE**

3-1-22



**PATIENT**

Punkin Martell

**SPECIES**

Canine

**BREED**

Australian Shepherd

**SEX**

FS

**AGE**

2 Years

**INTERPRETED BY**

Sebastian Schaub, DVM  
Dr. med. vet. DipECVDI

**HOSPITAL NAME**

Ruidoso Animal Clinic

**REFERRING VET**

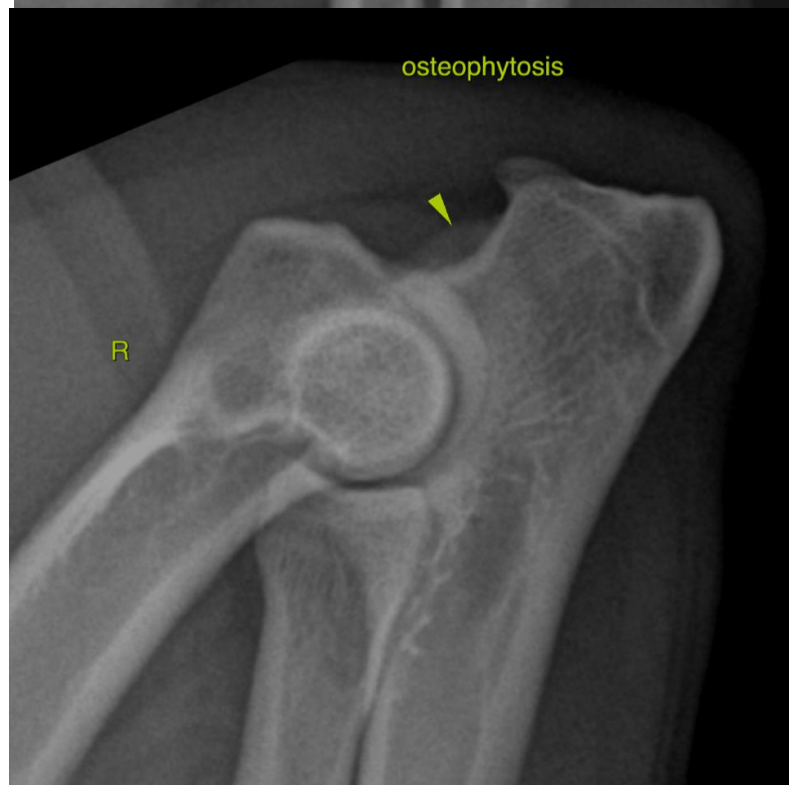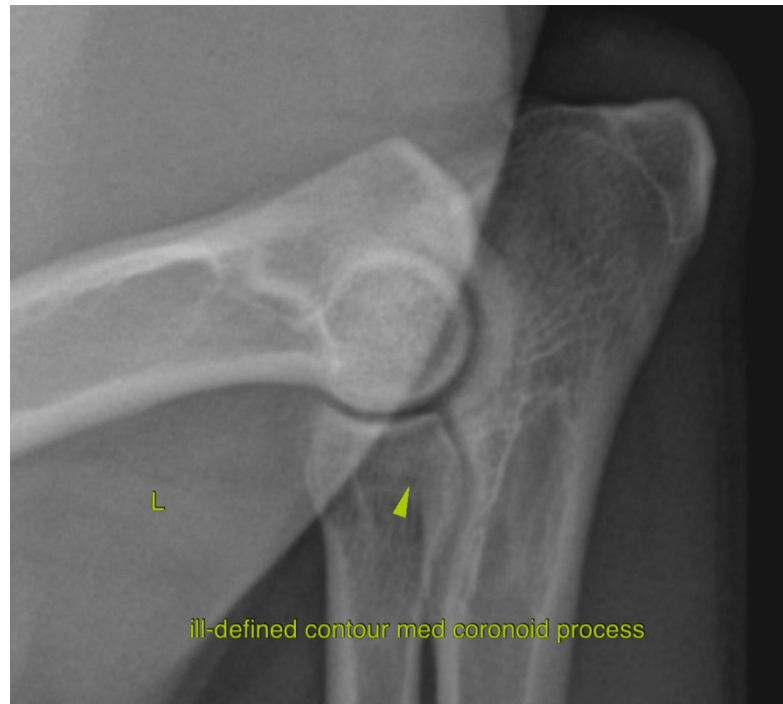
Amanda Favis

**INVOICE**

50620

**DATE**

3-1-22





**PATIENT**

Punkin Martell

**SPECIES**

Canine

**BREED**

Australian Shepherd

**SEX**

FS

**AGE**

2 Years

**INTERPRETED BY**

Sebastian Schaub, DVM  
Dr. med. vet. DipECVDI

**HOSPITAL NAME**

Ruidoso Animal Clinic

**REFERRING VET**

Amanda Favis

**INVOICE**

50620

**DATE**

3-1-22

The information and recommendations provided are based on the images presented by the referring veterinarian/sonographer. No evaluation can be communicated regarding pathology that was not visible in the image/video clips provided.

Thank you for this referral. If the clinical or image interpretation does not parallel your findings or if I can be of any further assistance please contact me.

**Sebastian Schaub**, Sebastian Schaub, DVM, Dr. med. vet. DipECVDI  
sebast.schaub@gmail.com