



**PATIENT PRESENTING CLINICAL SIGNS**

Grizz Joyce Pt has been severely paraparetic since a fall a week ago with marked back pain. He is known to have a history of IVDD. However, in the two days he has also started having vomiting a couple of times a day. He is eating still and keeping some food down. Diarrhea has not been reported, but there is evidence of it in the perianal fur.

**SPECIES** Abnormal PE/Chem/CBC/UA Results: CBC shows eosinophilia, chems are wnl. T4 wnl. UA is pending.

Canine

**BREED** Radiographs of the abdomen in three imaging planes are provided for review.

Peke

**SEX** The intervertebral disc spaces along the thoracolumbar junction are moderately narrowed and moderate spondylosis formation is seen.

Male Neutered

**AGE** The serosal detail is maintained throughout the peritoneal and retroperitoneal space.

10 Years

**INTERPRETED BY** The liver is appropriate in position, size and presents uniform opacity.

Sebastian Schaub, DVM Dr. med. vet. DipECVDI

The splenic head is in the anticipated position and within normal limits for size and opacity. The splenic body and tail are considered normal for position, size, shape and opacity.

**HOSPITAL NAME** Both kidneys are seen and present with normal size, shape, delineation and opacity. The urinary bladder is in its anticipated position. No radiopaque calculi are noted throughout the upper and lower urinary tract.

Friendship Springs Veterinary Care

**REFERRING VET** The stomach is in its anticipated position and presents normal content.

Trae Cutchin

The small intestinal loops are of even diameter and non-dilated, a small amount of gas is seen within the small intestinal loops and considered within normal limits.

The colon is seen in the expected position and presents with appropriate content.

- INVOICE**
- Chronic discopathy thoracolumbar junction
  - Cutaneous mass left craniolateral abdominal wall
  - Spondylosis deformans
- 50650

**DATE** **INTERPRETATION OF THE FINDINGS & FURTHER RECOMMENDATIONS**

3-1-22 No abnormalities are appreciated, explaining the history of vomiting. There is no evidence of radiopaque foreign material or signs for gastrointestinal mechanical obstruction. In conjunction with potential discopathy, pancreatitis and/or gastritis are considerations here.



**PATIENT**

Grizz Joyce

**SPECIES**

Canine

**BREED**

Peke

**SEX**

Male Neutered

**AGE**

10 Years

**INTERPRETED BY**

Sebastian Schaub, DVM  
Dr. med. vet. DipECVDI

**HOSPITAL NAME**

Friendship Springs  
Veterinary Care

**REFERRING VET**

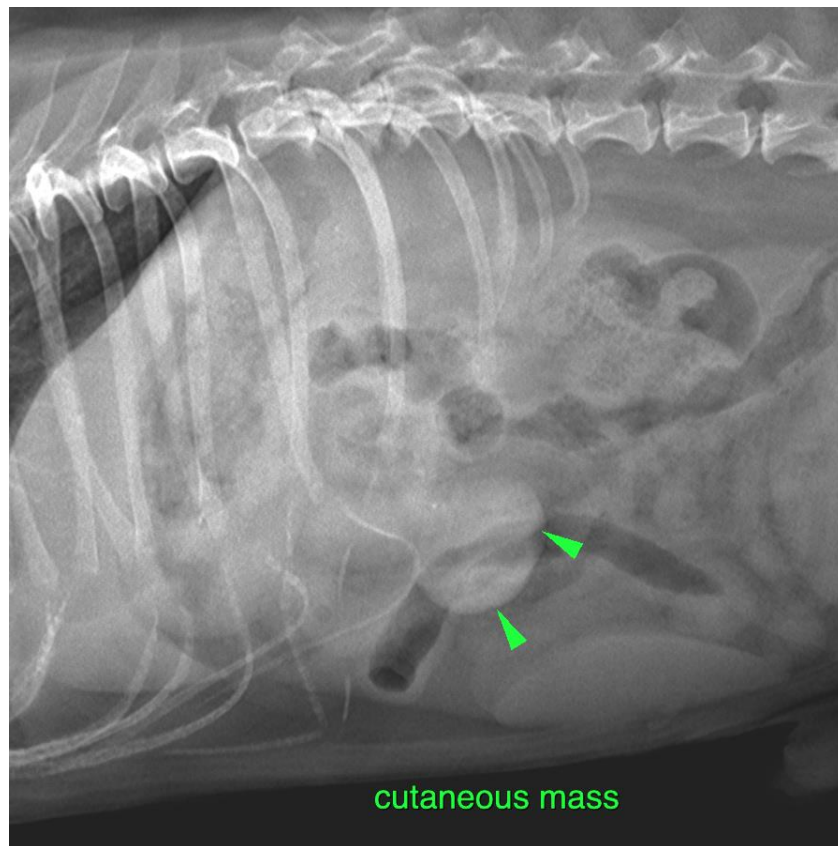
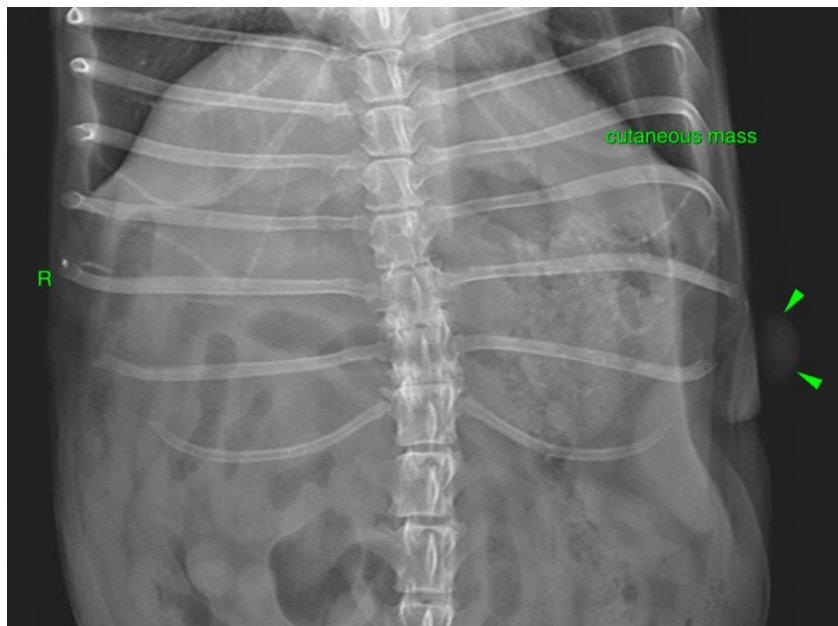
Trae Cutchin

**INVOICE**

50650

**DATE**

3-1-22





**PATIENT**

Grizz Joyce

**SPECIES**

Canine

**BREED**

Peke

**SEX**

Male Neutered

**AGE**

10 Years

**INTERPRETED BY**

Sebastian Schaub, DVM  
Dr. med. vet. DipECVDI

**HOSPITAL NAME**

Friendship Springs  
Veterinary Care

**REFERRING VET**

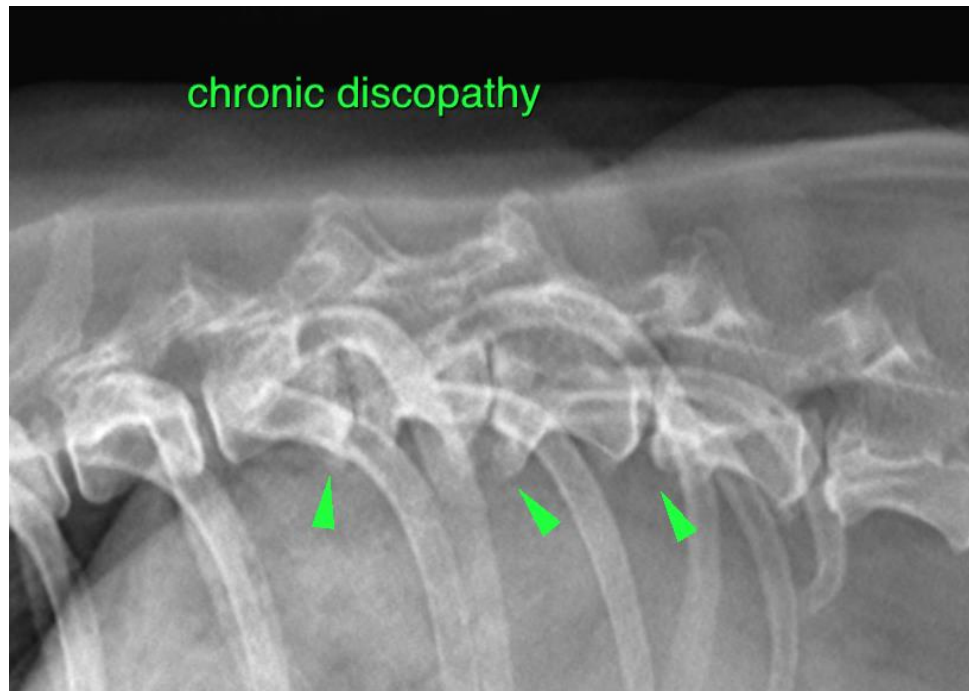
Trae Cutchin

**INVOICE**

50650

**DATE**

3-1-22



The information and recommendations provided are based on the images presented by the referring veterinarian/sonographer. No evaluation can be communicated regarding pathology that was not visible in the image/video clips provided.

Thank you for this referral. If the clinical or image interpretation does not parallel your findings or if I can be of any further assistance please contact me.

**Sebastian Schaub**, Sebastian Schaub, DVM, Dr. med. vet. DipECVDI  
sebast.schaub@gmail.com