

**PATIENT**

Daisy Tooman

SPECIES

Canine

BREED

Saint Bernard Mix

SEX

FS

AGE

9 Years, 1 Month

INTERPRETED BYSebastian Schaub, DVM
Dr. med. vet. DipECVDI**HOSPITAL NAME**Gentle Doctor Animal
Hospital**REFERRING VET**Megan Belfiore-
DiGiacomo**INVOICE**

50623

DATE

3-1-22

PRESENTING CLINICAL SIGNS

Daisy presented for routine PDT today. Once sedated, we were unable to get her jaw opened more than 3cm. She would chatter intensely as well with any pressure/tension on her mandible. We were unable to get her intubated and the procedure was cancelled. Skull films take to evaluate TMJ region. After discussion with owner, frequent chattering noted at home over the last few months. Previous head CT January 2021. No TMJ issues reported at that time. Patient number #19907C.

RADIOGRAPHIC STUDY OF THE SKULL

Radiographs of the skull in three imaging planes are provided for review.

RADIOGRAPHIC FINDINGS

Advanced shell like mineralization of the external ear canals are appreciated.

Both temporomandibular joints are in situ and present smooth osseous margins, unremarkable.

The tympanic bulla in the oblique projection marked with 'R' is moderately thickened.

The remainder of the osseous and soft tissue structures of the skull are within normal limits.

RADIOGRAPHIC DIAGNOSIS

- Chronic otitis externa with dystrophic mineralization
- Otitis media – right sided?
- Normal temporomandibular joints

INTERPRETATION OF THE FINDINGS & FURTHER RECOMMENDATIONS

The radiographic study of the skull presents no abnormalities, explaining the presenting clinical signs. No overt osseous changes are appreciated, but the unilateral otitis media. Rule out chronic masticatory muscle myositis or soft tissue inflammation/neoplasm. Complementing workup by a CT study of the skull appears beneficial.



PATIENT

Daisy Tooman

SPECIES

Canine

BREED

Saint Bernard Mix

SEX

FS

AGE

9 Years, 1 Month

INTERPRETED BY

Sebastian Schaub, DVM
Dr. med. vet. DipECVDI

HOSPITAL NAME

Gentle Doctor Animal
Hospital

REFERRING VET

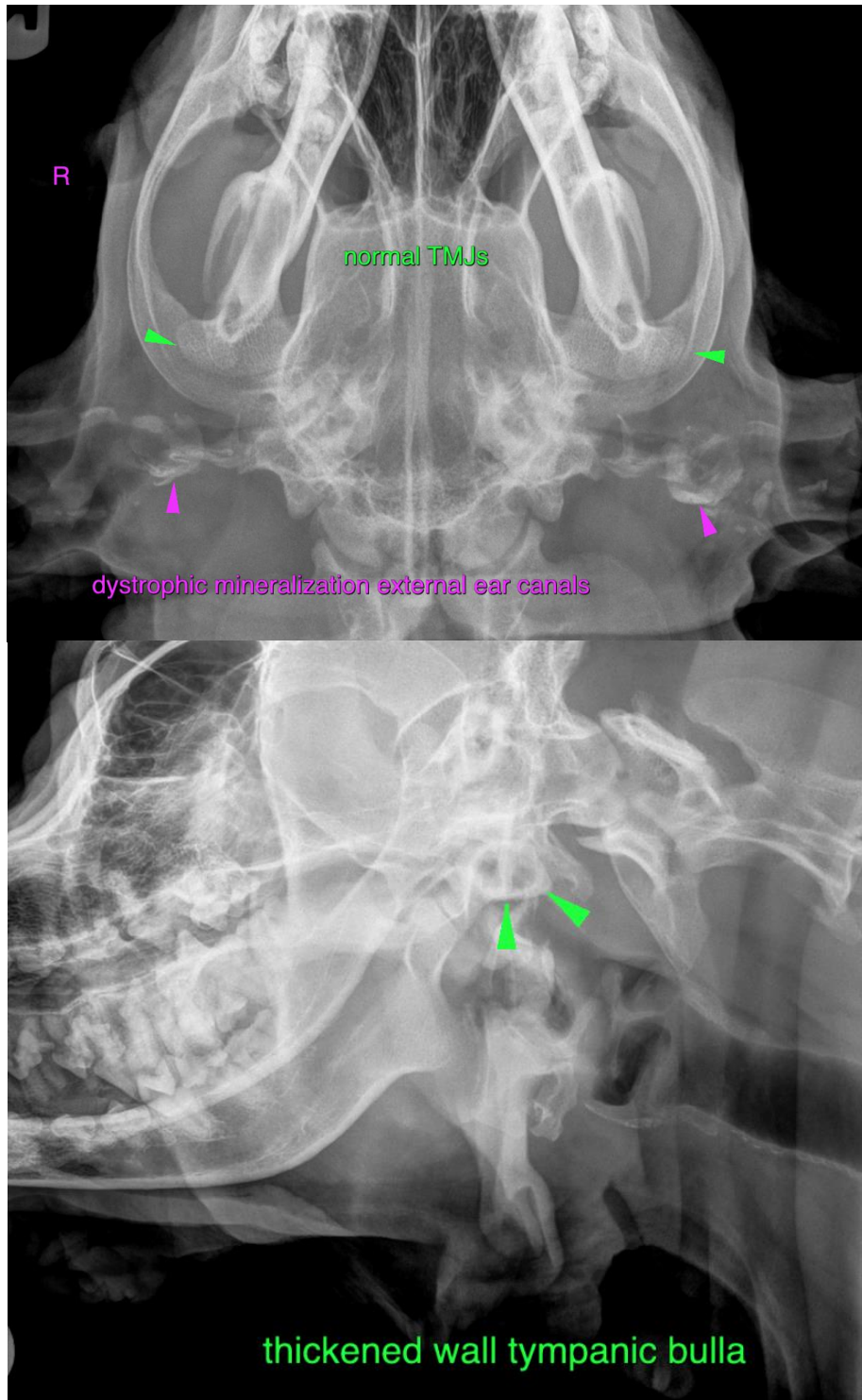
Megan Belfiore-
DiGiacomo

INVOICE

50623

DATE

3-1-22





PATIENT

Daisy Tooman

SPECIES

Canine

BREED

Saint Bernard Mix

SEX

FS

AGE

9 Years, 1 Month

INTERPRETED BY

Sebastian Schaub, DVM
Dr. med. vet. DipECVDI

HOSPITAL NAME

Gentle Doctor Animal
Hospital

REFERRING VET

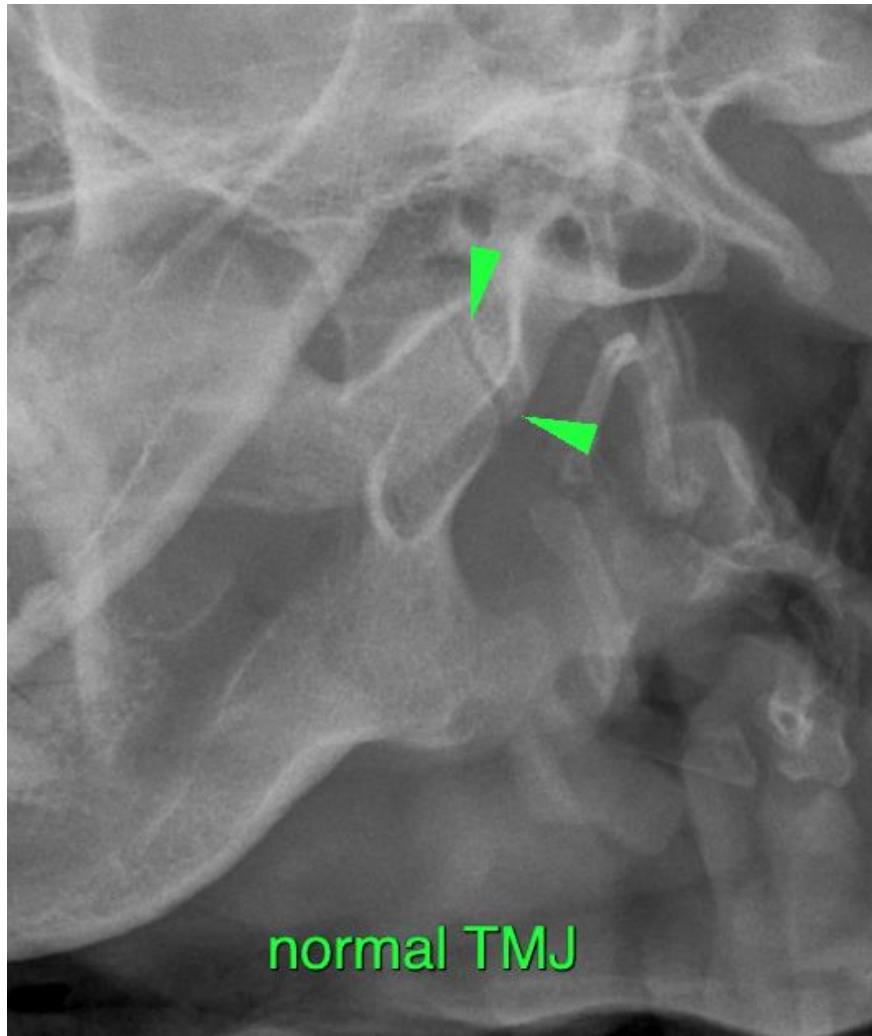
Megan Belfiore-
DiGiacomo

INVOICE

50623

DATE

3-1-22



The information and recommendations provided are based on the images presented by the referring veterinarian/sonographer. No evaluation can be communicated regarding pathology that was not visible in the image/video clips provided.

Thank you for this referral. If the clinical or image interpretation does not parallel your findings or if I can be of any further assistance please contact me.

Sebastian Schaub, Sebastian Schaub, DVM, Dr. med. vet. DipECVDI
sebast.schaub@gmail.com