



PATIENT

Penny Bachman

SPECIES

Canine

BREED

Mixed

SEX

Spayed Female

AGE

10Y

WEIGHT

68lbs

INTERPRETED BY

Sebastian Schaub, DVM
Dr. med. vet.
DipECVDI

IMAGING PERFORMED BY

Kelsey McCloskey, LVT

HOSPITAL NAME

Advanced Animal
Imaging

REFERRING VET

Blair Hollowell, DVM

INVOICE

73666

DATE

2-9-26

PRESENTING CLINICAL SIGNS

Chronic head shaking despite no signs of external ear infection. Concern for inner ear issues

COMPUTED TOMOGRAPHY OF THE SKULL & THORAX

A high resolution pre- and post-contrast CT study of the skull and a post contrast CT study of the thorax is provided for review.

COMPUTED TOMOGRAPHIC FINDINGS

Skull

Multiple teeth are absent.

The nasal cavity presents the expected aerated spaces between thin & even conchae and turbinates with smooth mucosal lining.

Both temporomandibular joints present congruent joint spaces with even subchondral bone surfaces and are considered within normal limits.

Both tympanic bullae are aerated, the mucosal lining is not seen, the bony wall is smooth and thin. The external ear canals are within normal limits.

The brain presents no deviation from normal anatomy and symmetry. The brain parenchyma is homogeneous and within normal limits for attenuation and distribution of contrast enhancement. The ventricular system is non-dilated and symmetric.

In the left retropharyngeal space, medial to the left medial retropharyngeal lymph node, a uniform soft tissue attenuating and strong contrast enhancing nodule mass is seen, measuring 12 x 11 x 13 mm. In the periphery of the left retropharyngeal nodule, multiple tortuous vessels are seen.

The submandibular and medial retropharyngeal lymph nodes are small and elongated with a normal short-to-long-axis-ratio is < 0.5, the attenuation and contrast enhancement pattern is uniform.

Thorax

Along the thoracic spine, multifocal spondylosis formation is seen.

The sternal, cranial mediastinal and tracheobronchial lymph nodes are small elongated with a normal short-to-long-axis-ratio is < 0.5, the attenuation and contrast enhancement pattern is uniform and considered within normal limits.

The cardiovascular structures including the pulmonary vasculature are within normal limits.

The bronchial tree presents with regular branching and tapers uniformly towards the periphery as expected, the bronchial walls are thin and smooth. The bronchus-to-artery ratio is within normal limits.

The lung parenchyma presents the expected architecture and attenuation behavior.

Small incidental gas pockets are seen within the esophageal lumen; there is no evidence of abnormal dilation.

COMPUTED TOMOGRAPHIC DIAGNOSIS

- Small left retropharyngeal soft tissue nodule
- Spondylosis deformans thoracic spine
- Multiple absent teeth



PATIENT

Penny Bachman

SPECIES

Canine

BREED

Mixed

SEX

Spayed Female

AGE

10Y

WEIGHT

68lbs

INTERPRETED BY

Sebastian Schaub, DVM
Dr. med. vet.
DipECVDI

IMAGING PERFORMED BY

Kelsey McCloskey, LVT

HOSPITAL NAME

Advanced Animal
Imaging

REFERRING VET

Blair Hollowell, DVM

INVOICE

73666

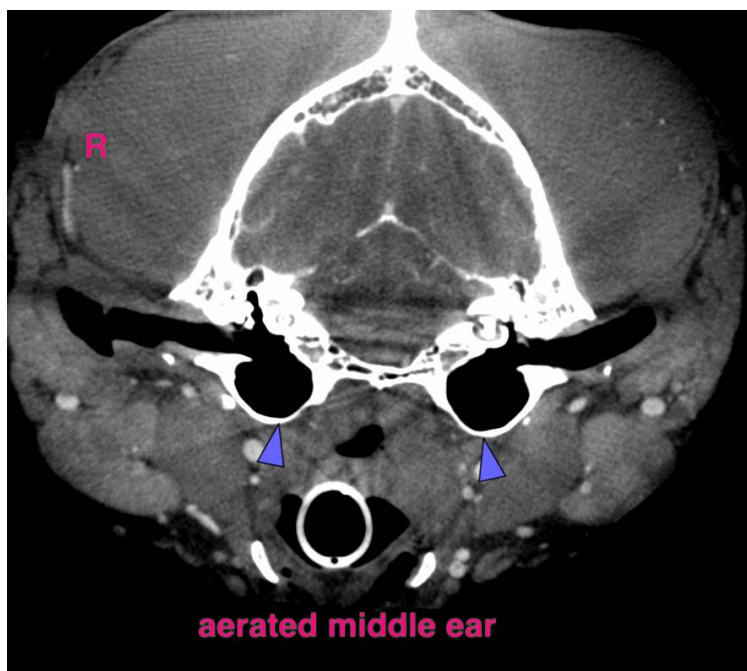
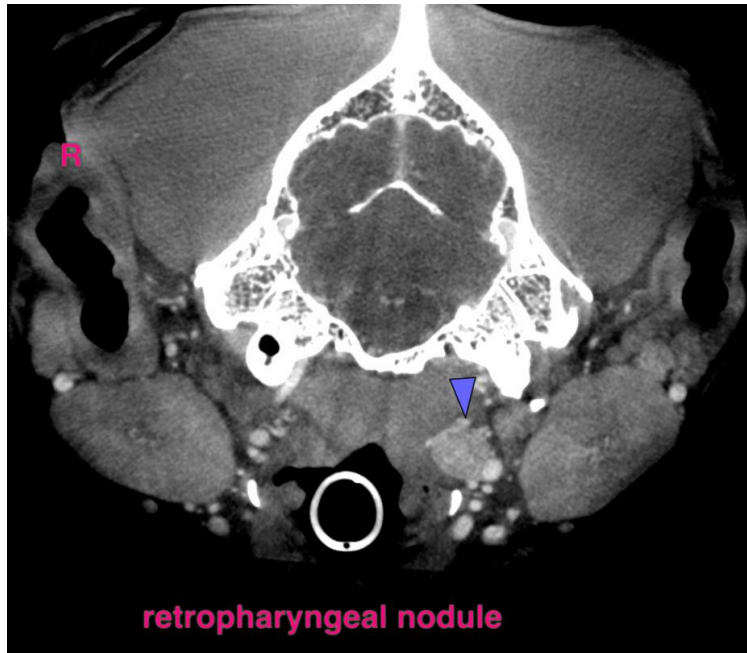
DATE

2-9-26

- No evidence of pulmonary metastatic disease

INTERPRETATION OF THE FINDINGS & FURTHER RECOMMENDATIONS

The small retropharyngeal soft tissue nodule is consistent with primary soft tissue neoplasia – the most likely differentials are paraganglioma or ectopic thyroid carcinoma. Surgical management is feasible. If the nodule is associated with the presenting clinical signs is unclear.





PATIENT

Penny Bachman

SPECIES

Canine

BREED

Mixed

SEX

Spayed Female

AGE

10Y

WEIGHT

68lbs

INTERPRETED BY

Sebastian Schaub, DVM
Dr. med. vet.
DipECVDI

IMAGING PERFORMED BY

Kelsey McCloskey, LVT

HOSPITAL NAME

Advanced Animal
Imaging

REFERRING VET

Blair Hollowell, DVM

INVOICE

73666

DATE

2-9-26

The information and recommendations provided are based on the images presented by the referring veterinarian/sonographer. No evaluation can be communicated regarding pathology that was not visible in the image/video clips provided.

Thank you for this referral. If the clinical or image interpretation does not parallel your findings or if I can be of any further assistance please contact me.

Sebastian Schaub, Sebastian Schaub, DVM, Dr. med. vet. DipECVDI
info@sonopath.com