



## PATIENT

Indi Stevenson

## SPECIES

Canine

## BREED

Shepherd X

## SEX

MN

## AGE

13Y, 8M, 6D

## WEIGHT

33.10kg

## INTERPRETED BY

Sebastian Schaub, DVM  
Dr. med. vet.  
DipECVDI

## IMAGING PERFORMED BY

AMC

## HOSPITAL NAME

Green Dog Dental and  
Wellness

## REFERRING VET

Dr. Geist

## INVOICE

73665

## DATE

2-9-26

## PRESENTING CLINICAL SIGNS

- Hip pain, trouble getting up after sleeping or resting for long periods of time
- Resistant and painful on R shoulder extension, elbow flexion bilaterally, hip extension bilaterally, and R stifle flexion. Grade 3/5 lameness, lameness visible at a walk.

## RADIOGRAPHIC STUDY OF THE PELVIS AND STIFLE JOINTS

A complete set of radiographs of the pelvis and the stifle joints is provided for review.

## RADIOGRAPHIC FINDINGS

The osseous and surrounding soft tissue structures of the pelvis are within normal limits. Both coxofemoral joints present smooth osseous margins and congruent joint spaces.

Both stifle joints present smooth margins of the periarticular bones and no evidence of an intracapsular soft tissue swelling. The patella of both stifle joints is in situ.

In the pictured parts of the abdomen, the caudal extremity of the spleen presents focal convex shaped bulging of the ventral surface.

## RADIOGRAPHIC DIAGNOSIS

- Splenic soft tissue nodule
- Normal pelvis
- Normal stifle joints

## INTERPRETATION OF THE FINDINGS & FURTHER RECOMMENDATIONS

The radiographic study of the pelvis and stifle joints reveals no abnormalities and an underlying cause for the described clinical signs cannot be specified – there is no evidence of degenerative joint disease nor hip dysplasia or aggressive bone lesions.

The focal convex bulging of the splenic surface is indicative for splenic nodule – such as benign nodular hyperplasia, hematoma or neoplasia (e.g. sarcoma). Workup can be complemented by an abdominal ultrasound examination for confirmation.



## PATIENT

Indi Stevenson

## SPECIES

Canine

## BREED

Shepherd X

## SEX

MN

## AGE

13Y, 8M, 6D

## WEIGHT

33.10kg

## INTERPRETED BY

Sebastian Schaub, DVM  
Dr. med. vet.  
DipECVDI

## IMAGING PERFORMED BY

AMC

## HOSPITAL NAME

Green Dog Dental and  
Wellness

## REFERRING VET

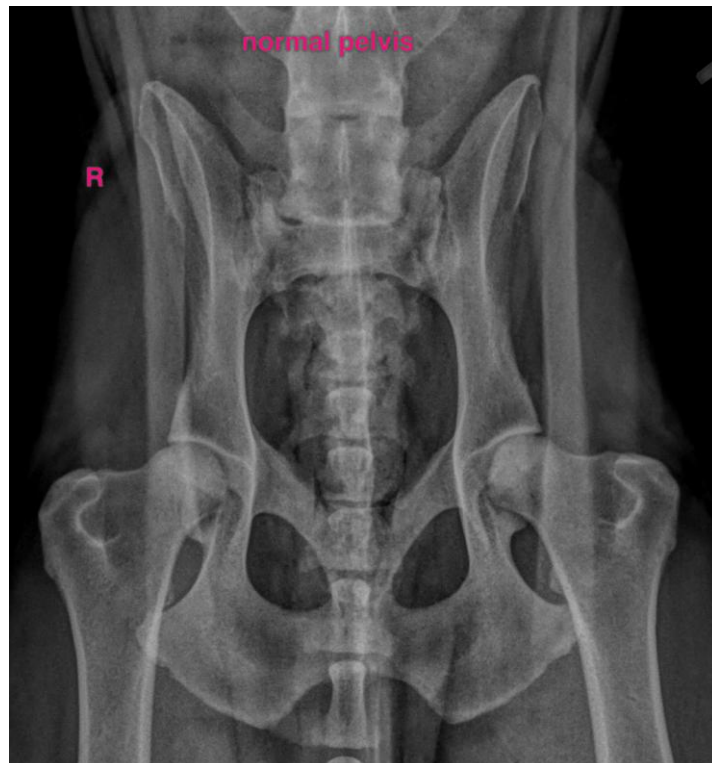
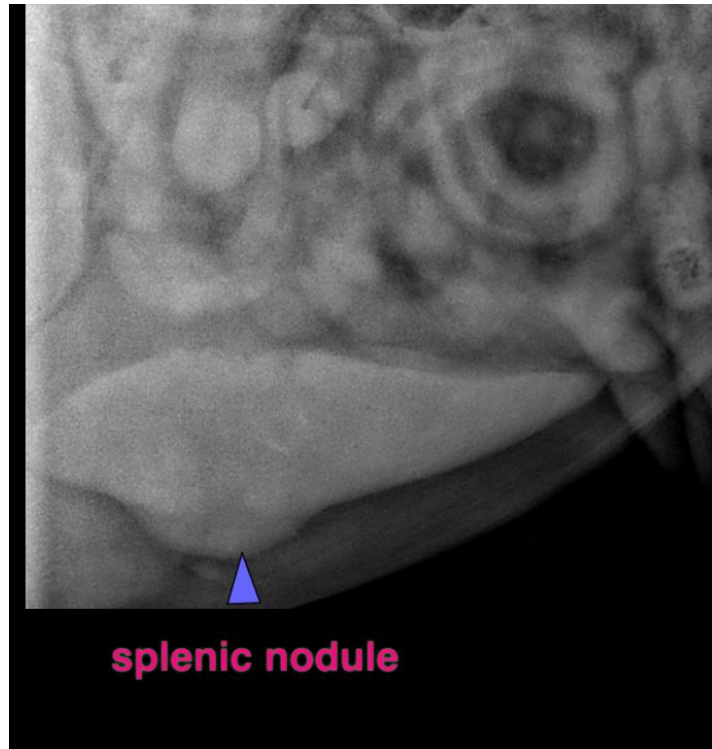
Dr. Geist

## INVOICE

73665

## DATE

2-9-26





## PATIENT

Indi Stevenson

## SPECIES

Canine

## BREED

Shepherd X

## SEX

MN

## AGE

13Y, 8M, 6D

## WEIGHT

33.10kg

## INTERPRETED BY

Sebastian Schaub, DVM  
Dr. med. vet.  
DipECVDI

## IMAGING PERFORMED BY

AMC

## HOSPITAL NAME

Green Dog Dental and  
Wellness

## REFERRING VET

Dr. Geist

## INVOICE

73665

## DATE

2-9-26

The information and recommendations provided are based on the images presented by the referring veterinarian/sonographer. No evaluation can be communicated regarding pathology that was not visible in the image/video clips provided.

Thank you for this referral. If the clinical or image interpretation does not parallel your findings or if I can be of any further assistance please contact me.

**Sebastian Schaub**, Sebastian Schaub, DVM, Dr. med. vet. DipECVDI  
[info@sonopath.com](mailto:info@sonopath.com)