



PATIENT

Cutie Valencia

SPECIES

Feline

BREED

Shih Tzu

SEX

Female Spayed

AGE

13Y

WEIGHT

11lbs

INTERPRETED BY

Sebastian Schaub, DVM
Dr. med. vet.
DipECVDI

IMAGING PERFORMED BY

Dr. Thomas

HOSPITAL NAME

Animal Clinic of
Queens

REFERRING VET

Dr. Thomas

INVOICE

73656

DATE

2-9-26

PRESENTING CLINICAL SIGNS

Pt has a history of hepatomegaly and elevated liver values

RADIOGRAPHIC STUDY OF THE THORAX & ABDOMEN

A complete set of radiographs of the thorax and abdomen are provided for review.

RADIOGRAPHIC FINDINGS

Thorax

The surrounding bony structures are within normal limits.

The extrathoracic soft tissues present homogeneous without abnormalities.

The heart is of normal size and shape; there is no evidence of cardiac chamber or vascular enlargement. The pulmonary vasculature is within normal limits.

The cranial mediastinum presents the expected soft tissue opacity. The mediastinal width is less than twice the width of the vertebral column at the same level.

The trachea is normal in diameter and presents the anticipated course. The luminal outline of the trachea is smooth.

The bronchial tree presents with thin walls and tapers uniformly towards the periphery as expected.

The lung parenchyma presents the expected architecture and opacity; the intrapulmonary vascular branching is seen up to the third order lung vessels.

The diaphragm is well delineated with even surface and the expected mild cranial bulging of the diaphragmatic cupola.

Abdomen

The surrounding bony structures are within normal limits.

No abnormalities of the extraabdominal soft tissues are noted. The abdominal wall is smooth and thin.

The serosal detail is maintained throughout the peritoneal and retroperitoneal space.

The hepatic volume is increased, the caudoventral hepatic margins are rounded and are protruding caudally beyond the costal arch. The gastric axis is deviated caudally. The hepatic parenchyma has a homogeneous soft tissue opacity.

The splenic head is in the anticipated position and within normal limits for size and opacity. The splenic body and tail are considered normal for position, size, shape and opacity.

Both kidneys are seen and present with normal size, shape, delineation and opacity. Mineral opaque material is seen in the image plane of the renal pelvis bilaterally. The urinary bladder is in its anticipated position. No radiopaque calculi are noted throughout the lower urinary tract.

The stomach is in its anticipated position and presents normal content.

The small intestinal loops are of even diameter and non-dilated, a small amount of gas is seen within the small intestinal loops and considered within normal limits.

The colon is seen in the expected position and presents with appropriate content.



PATIENT

Cutie Valencia

SPECIES

Feline

BREED

Shih Tzu

SEX

Female Spayed

AGE

13Y

WEIGHT

11lbs

INTERPRETED BY

Sebastian Schaub, DVM
Dr. med. vet.
DipECVDI

IMAGING PERFORMED BY

Dr. Thomas

HOSPITAL NAME

Animal Clinic of
Queens

REFERRING VET

Dr. Thomas

INVOICE

73656

DATE

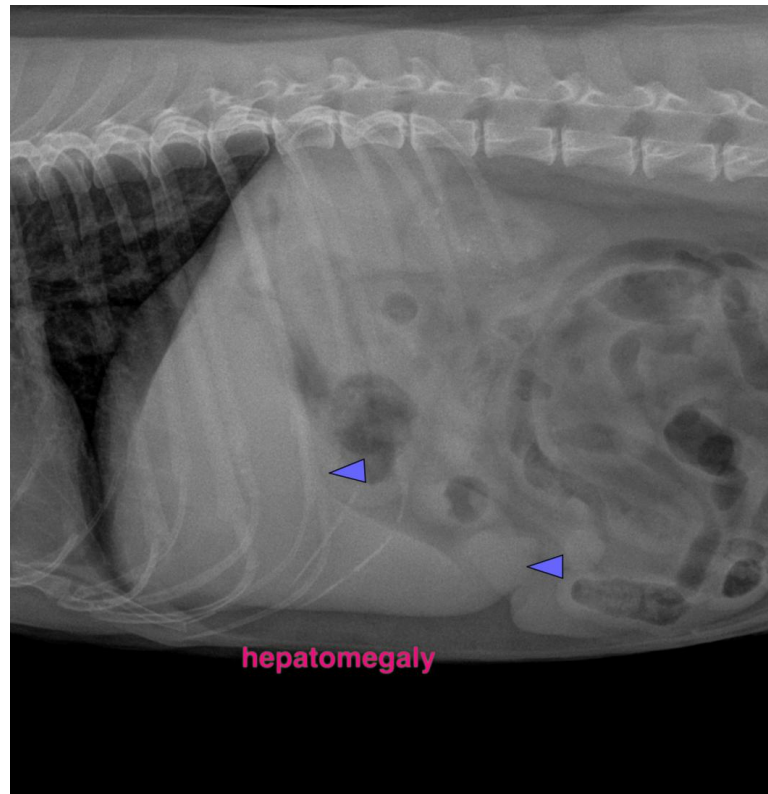
2-9-26

RADIOGRAPHIC DIAGNOSIS

- Hepatomegaly
- Nephrolithiasis
- Normal thorax

INTERPRETATION OF THE FINDINGS & FURTHER RECOMMENDATIONS

Potentials for the hepatomegaly include metabolic hepatic disease/steroid induced hepatopathy ± hepatitis or less likely diffuse neoplastic infiltration. Ultrasound can be used for specification and will allow FNA sampling as advanced minimally invasive diagnostic tool.





PATIENT

Cutie Valencia

SPECIES

Feline

BREED

Shih Tzu

SEX

Female Spayed

AGE

13Y

WEIGHT

11lbs

INTERPRETED BY

Sebastian Schaub, DVM
Dr. med. vet.
DipECVDI

IMAGING PERFORMED BY

Dr. Thomas

HOSPITAL NAME

Animal Clinic of
Queens

REFERRING VET

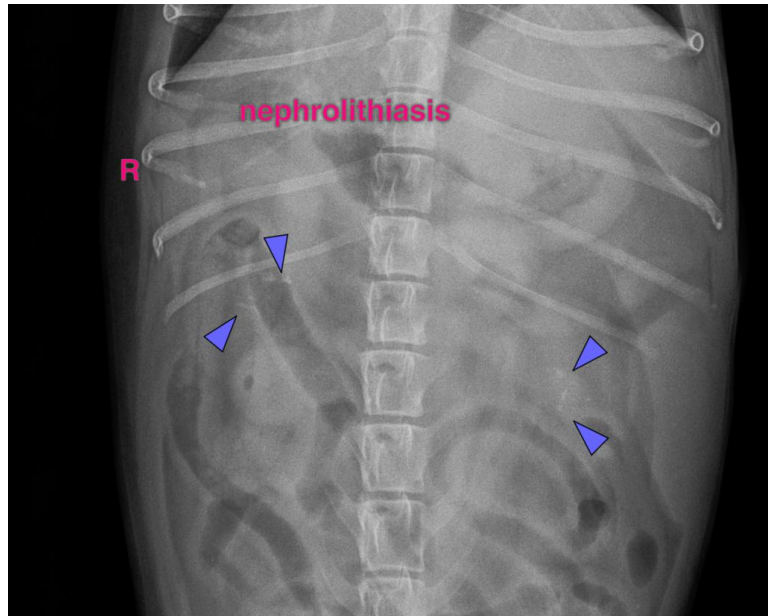
Dr. Thomas

INVOICE

73656

DATE

2-9-26



The information and recommendations provided are based on the images presented by the referring veterinarian/sonographer. No evaluation can be communicated regarding pathology that was not visible in the image/video clips provided.

Thank you for this referral. If the clinical or image interpretation does not parallel your findings or if I can be of any further assistance please contact me.

Sebastian Schaub, Sebastian Schaub, DVM, Dr. med. vet. DipECVDI
info@sonopath.com