



PATIENT

Appa McShea

SPECIES

Canine

BREED

Leonberger

SEX

MN

AGE

7 Years

INTERPRETED BY

Sebastian Schaub, DVM
Dr. med. vet. DipECVDI

HOSPITAL NAME

Lambs Gap Animal
Hospital

REFERRING VET

Dr. Jennifer Todd

INVOICE

56665

DATE

2-9-23

PRESENTING CLINICAL SIGNS

Appa is a seven year old, MN, Leonberger with a history of chronic bilateral front limb lameness (with the right front being worse than the left front). He has had rehab therapy for IVDD and shoulder tendinopathies in the past. He has also had PRP injections in his right shoulder in the past, his owner did not feel the treatment helped. At his latest exam Appa showed mild RF lameness and off-loading of weight at a stand. Meds include carprofen, methocarbamol, omeprazole and dasuquin advanced. Both shoulders and both flexed elbows are included for your evaluation. Thank you.

RADIOGRAPHIC STUDY OF THE SHOULDER AND ELBOW JOINTS

A complete set of radiographs of front limbs is provided for review.

RADIOGRAPHIC FINDINGS

The caudal margin of the glenoid fossa bilaterally is mildly irregular. The intertubercular sulcus of the humerus bilaterally presents an increased sclerosis, L>R. The surrounding soft tissue structures of the shoulder joints are unremarkable.

Both elbow joints present smooth osseous margins of the periarticular bones. The contour of the medial coronoid process of the elbow joints is well-defined and has a homogeneous density.

RADIOGRAPHIC DIAGNOSIS

- Sclerosis bicipital groove humerus bilaterally
- Mild degenerative osteoarthritis shoulder joints bilaterally
- Normal elbow joints bilaterally

INTERPRETATION OF THE FINDINGS & FURTHER RECOMMENDATIONS

The sclerosis of the bicipital groove is suggestive for tendinopathy of the bicipital tendon of both shoulder joints – ultrasound might be considered as advanced imaging modality for evaluation of the bicipital tendon and rotator cuff.



PATIENT

Appa McShea

SPECIES

Canine

BREED

Leonberger

SEX

MN

AGE

7 Years

INTERPRETED BY

Sebastian Schaub, DVM
Dr. med. vet. DipECVDI

HOSPITAL NAME

Lambs Gap Animal
Hospital

REFERRING VET

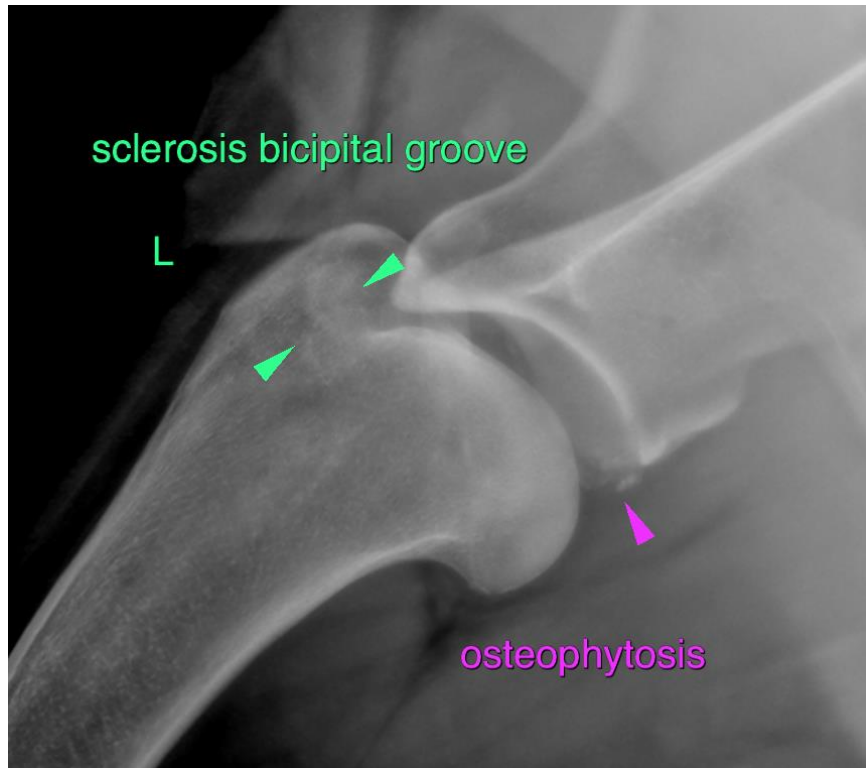
Dr. Jennifer Todd

INVOICE

56665

DATE

2-9-23



The information and recommendations provided are based on the images presented by the referring veterinarian/sonographer. No evaluation can be communicated regarding pathology that was not visible in the image/video clips provided.

Thank you for this referral. If the clinical or image interpretation does not parallel your findings or if I can be of any further assistance please contact me.

Sebastian Schaub, Sebastian Schaub, DVM, Dr. med. vet. DipECVDI
sebast.schaub@gmail.com