



PATIENT

Winston Fuhrman

PRESENTING CLINICAL SIGNS

Intermittent left forelimb lameness. Not responsive to Meloxicam. Minimum database of bloodwork performed and all within normal limits.

SPECIES

Canine

RADIOGRAPHIC STUDY OF THE SHOULDER AND ELBOW JOINTS

A full set of radiographs of the shoulder and elbow joints is provided for review.

BREED

Briard

RADIOGRAPHIC FINDINGS

Both shoulder joints present smooth osseous margins and the surrounding soft tissue structures are within normal limits.

SEX

Male Neutered

The periarticular bones of the left elbow joint present moderate osteophyte new bone formation. The contour of the medial coronoid process of the left elbow joint is ill-defined.

Mild osteophyte formation is seen at the cranial aspect of the radius of the right elbow joint.

RADIOGRAPHIC DIAGNOSIS

- Suspect left sided pathology of the medial coronoid process
- Moderate degenerative osteoarthritis left elbow joint
- Mild degenerative osteoarthritis right elbow joint
- Normal shoulder joints

AGE

9 Years

INTERPRETED BY

Sebastian Schaub, DVM
Dr. med. vet. DipECVDI

INTERPRETATION OF THE FINDINGS & FURTHER RECOMMENDATIONS

The findings are compatible with degenerative joint disease of the left elbow joint, underlying coronoid disease – such as fragmented medial coronoid process - is considered most likely. The findings are a plausible cause for left front limb lameness. Check clinically if pain can be elicited by pressure on the medial coronoid process, supporting the diagnosis.

HOSPITAL NAME

North Idaho Animal
Hospital (VCA)

If there is suspicion for lameness originating from the shoulder joint, an ultrasound examination of the shoulder joint can be used to check for pathology of the bicipital tendon.

REFERRING VET

Dr. Jolee Stegemoller

INVOICE

50218

DATE

2-9-22



PATIENT

Winston Fuhrman

SPECIES

Canine

BREED

Briard

SEX

Male Neutered

AGE

9 Years

INTERPRETED BY

Sebastian Schaub, DVM
Dr. med. vet. DipECVDI

HOSPITAL NAME

North Idaho Animal
Hospital (VCA)

REFERRING VET

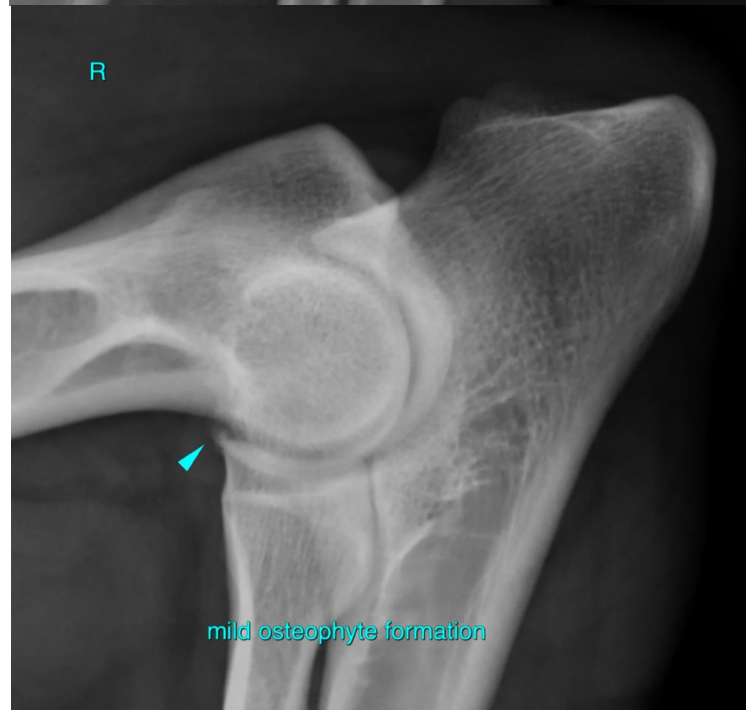
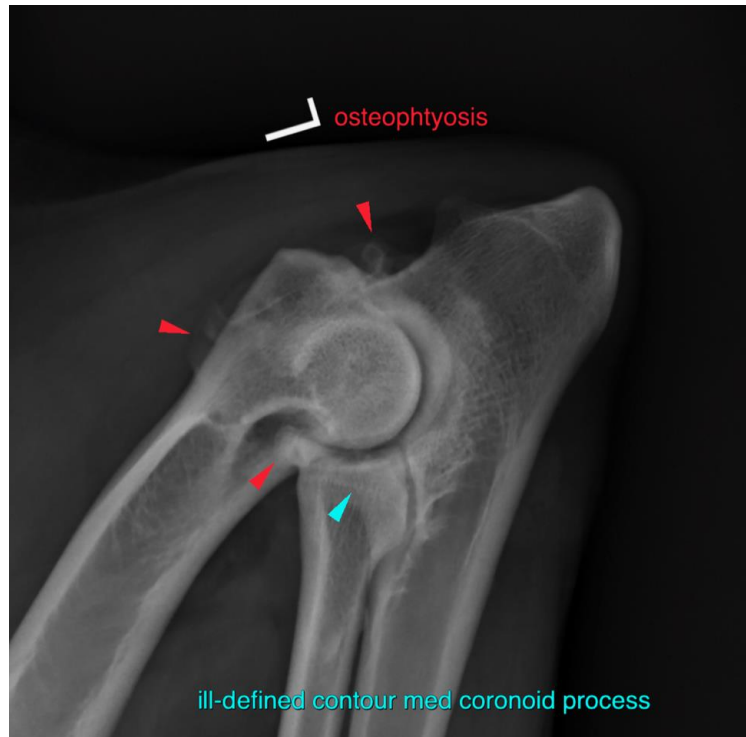
Dr. Jolee Stegemoller

INVOICE

50218

DATE

2-9-22





PATIENT

Winston Fuhrman

The information and recommendations provided are based on the images presented by the referring veterinarian/sonographer. No evaluation can be communicated regarding pathology that was not visible in the image/video clips provided.

SPECIES

Canine

Thank you for this referral. If the clinical or image interpretation does not parallel your findings or if I can be of any further assistance please contact me.

BREED

Briard

Sebastian Schaub, Sebastian Schaub, DVM, Dr. med. vet. DipECVDI
sebast.schaub@gmail.com

SEX

Male Neutered

AGE

9 Years

INTERPRETED BY

Sebastian Schaub, DVM
Dr. med. vet. DipECVDI

HOSPITAL NAME

North Idaho Animal
Hospital (VCA)

REFERRING VET

Dr. Jolee Stegemoller

INVOICE

50218

DATE

2-9-22