



PATIENT

Smith Ann Schmidt

PRESENTING CLINICAL SIGNS

Limping on the right back leg. Was intermittent yesterday. More consistent today. She couldn't squat to pee this morning. Victory can't think of any time they were playing that Smith Ann could have hurt herself. She doesn't like to put weight on that leg and will toe tap. Victory says the leg shakes. Victory says that Smith Ann pants a lot and had trouble getting out of her crate this morning. She tends to get situated and not move. Ambulatory X 4, Stifle appears comfortable
 Abnormal PE/Chem/CBC/UA Results: LAME RIGHT REAR SWELLING TO RIGHT HOCK DISCOMFORT TO FLEXION OF HOCK

SPECIES

Canine

BREED

Red Heeler

RADIOGRAPHIC STUDY OF THE STIFLE AND TARSAL JOINTS

Radiographs of the stifle and tarsal joints are provided for review.

RADIOGRAPHIC FINDINGS

SEX

F/spayed

Both stifle joints present a mild intracapsular soft tissue swelling, distorting the infrapatellar fat pad. The osseous margins of the stifle joint are smooth, and the patella is in situ.

AGE

3 Years, 1 Month

Both talocrural joints present with a mild periarticular soft tissue swelling. The osseous margins of the tarsal joints are smooth.

RADIOGRAPHIC DIAGNOSIS

- Articular swelling stifle & tarsal joints bilaterally

INTERPRETATION OF THE FINDINGS & FURTHER RECOMMENDATIONS

The swelling of multiple joints is concerning for immune mediated polyarthritis. As the radiographic changes are bilaterally symmetric, the odds for traumatic origin (e.g. distortion, tearing of ligaments) are considered less likely. There are no signs for degenerative joint disease, neither the stifle nor the tarsal joints. Recommend complementing workup by a synovial tap of the tarsal & stifle joints.

HOSPITAL NAME

Elizabeth Animal Hospital

REFERRING VET

Dr. Allyn

INVOICE

50220

DATE

2-9-22

Sebastian Schaub, DVM
 Dr. med. vet. DipECVDI



PATIENT

Smith Ann Schmidt

SPECIES

Canine

BREED

Red Heeler

SEX

F/spayed

AGE

3 Years, 1 Month

INTERPRETED BY

Sebastian Schaub, DVM
Dr. med. vet. DipECVDI

HOSPITAL NAME

Elizabeth Animal
Hospital

REFERRING VET

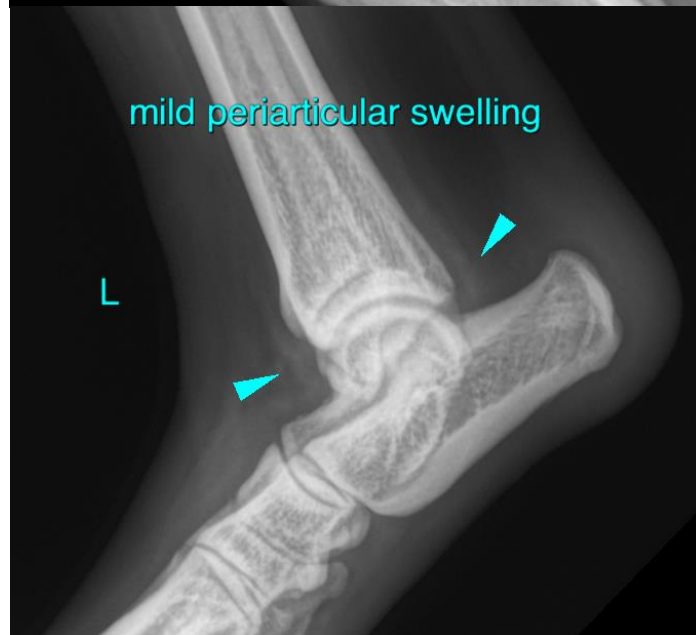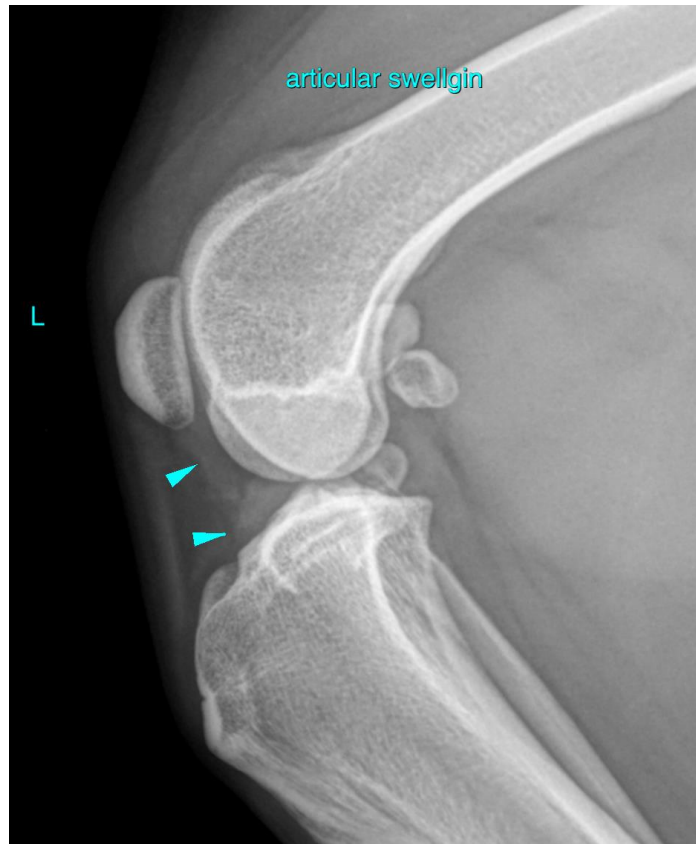
Dr. Allyn

INVOICE

50220

DATE

2-9-22





PATIENT

Smith Ann Schmidt

SPECIES

Canine

BREED

Red Heeler

SEX

F/spayed

AGE

3 Years, 1 Month

INTERPRETED BY

Sebastian Schaub, DVM
Dr. med. vet. DipECVDI

HOSPITAL NAME

Elizabeth Animal
Hospital

REFERRING VET

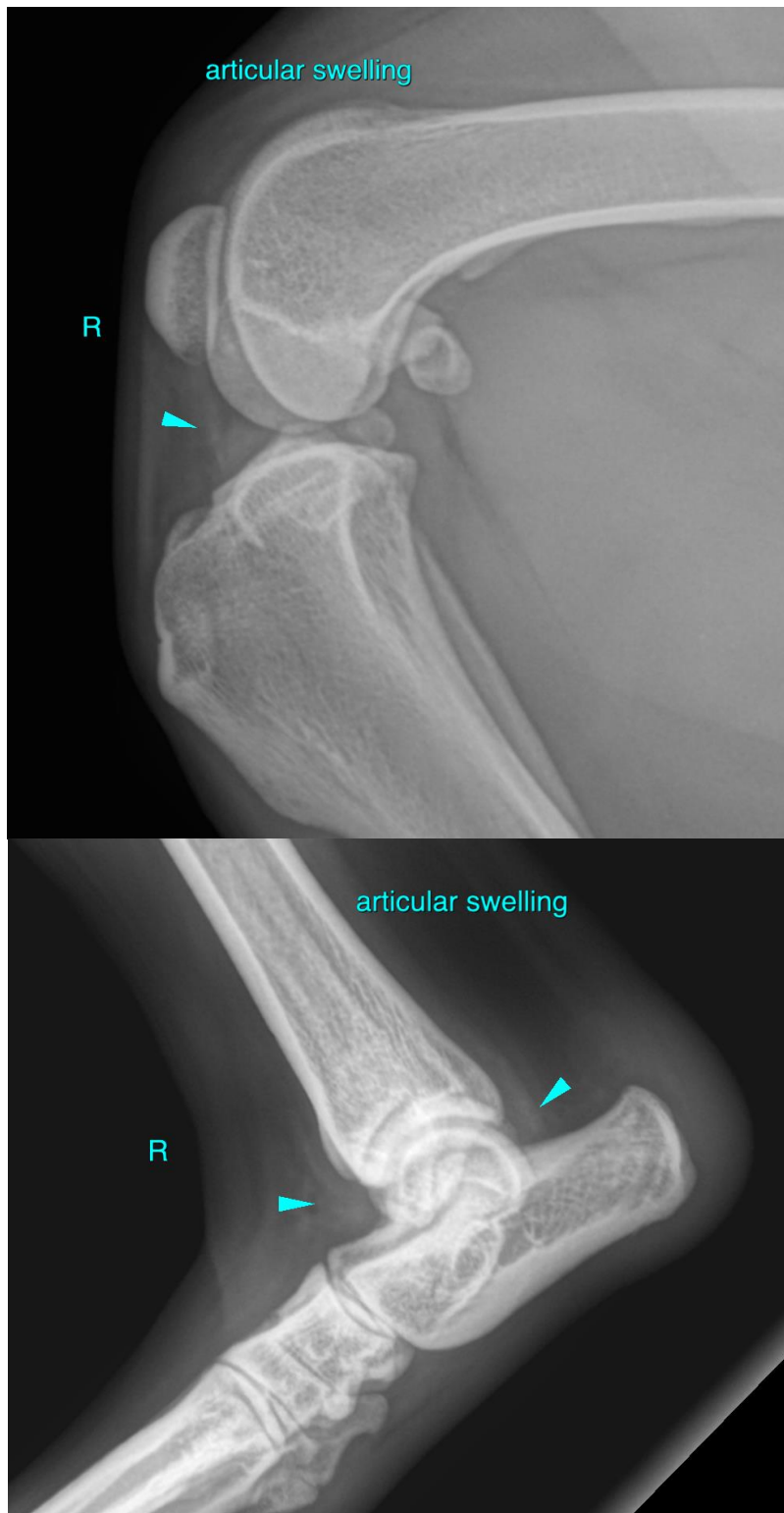
Dr. Allyn

INVOICE

50220

DATE

2-9-22





PATIENT

Smith Ann Schmidt

SPECIES

Canine

The information and recommendations provided are based on the images presented by the referring veterinarian/sonographer. No evaluation can be communicated regarding pathology that was not visible in the image/video clips provided.

BREED

Red Heeler

Thank you for this referral. If the clinical or image interpretation does not parallel your findings or if I can be of any further assistance please contact me.

Sebastian Schaub, Sebastian Schaub, DVM, Dr. med. vet. DipECVDI
sebast.schaub@gmail.com

SEX

F/spayed

AGE

3 Years, 1 Month

INTERPRETED BY

Sebastian Schaub, DVM
Dr. med. vet. DipECVDI

HOSPITAL NAME

Elizabeth Animal
Hospital

REFERRING VET

Dr. Allyn

INVOICE

50220

DATE

2-9-22