



PATIENT PRESENTING CLINICAL SIGNS

Havoc Caygle

2/8/22 Reason for visit: Was in last night, not able keep water down, vomiting medication, O believes PT is dehydrated. O is upset that PT was not put on SQ fluids last night. Questions: How has your pet been doing since last visit: Declining Current medications, doses, dosing schedule, last administered (Vitamins, supplements, prescribed medications): Cephalexin 500mg Do you have any new concerns: yes: dehydration, urinating often, diarrhea. Labored breathing Breathing very hard and you can see his chest retracting and he's out of breath. Noticed breathing changes over the weekend. Urinating around house for the last week which he never normally does and it was very concentrated and very dark with foam and he does have diarrhea. He is also throwing up bile as of yesterday. He hasn't been eating and has been eating less and less over the last week with his last food being dog food last night and he's only drinking water at this point. Loves treats but wants nothing to do with them today and also refusing to play with toys which is extremely unusual. No c/s. Previously on very high protein diet because he was a police dog, they took him off that since he retired 2020. O is worried his kidneys may not be filtering well. Rads approved, ultrasound approved Questions: What is your pet's birth date or approx. age: 10 Is your pet on any medications (Vitamins, supplements): No medications When did your pet last get medications (If applicable): na Has your pet been vaccinated in the last 1-3 years: Yes: Who is your primary veterinarian/clinic? Ogden Animal Hospital Has your pet traveled outside Utah within the last year: No Does your pet have any other current medical problems: No Is your pet indoor, outdoor, or both: Both What is your pet fed: Instinct Dog Food Any diagnostics done for this problem at another clinic since your last visit: No 2/7/22 Labored breathing Breathing very hard and you can see his chest retracting and he's out of breath. Noticed breathing changes over the weekend. Urinating around house for the last week which he never normally does and it was very

SPECIES

Canine

BREED

Belgian Sheperd

SEX

M

AGE

10

INTERPRETED BY

Sebastian Schaub, DVM
Dr. med. vet. DipECVDI

HOSPITAL NAME

Mountain West
Veterinary Hospital

REFERRING VET

Jeff Simmons

INVOICE

50193

DATE

2-9-22

concentrated and very dark with foam and he does have diarrhea. He is also throwing up bile as of yesterday. He hasn't been eating and has been eating less and less over the last week with his last food being dog food last night and he's only drinking water at this point. Loves treats but wants nothing to do with them today and also refusing to play with toys which is extremely unusual. No c/s. Previously on very high protein diet because he was a police dog, they took him off that since he retired 2020. O is worried his kidneys may not be filtering well. Rads approved, ultrasound approved Questions: What is your pet's birth date or approx. age: 10 Is your pet on any medications (Vitamins, supplements): No medications When did your pet last get medications (If applicable): na Has your pet been vaccinated in the last 1-3 years: Yes: Who is your primary veterinarian/clinic? Ogden Animal Hospital Has your pet traveled outside Utah within the last year: No Does your pet have any other current medical problems: No Is your pet indoor, outdoor, or both: Both What is your pet fed: Instinct Dog Food
Abnormal PE/Chem/CBC/UA Results: Labored breathing Breathing very hard and you can see his chest retracting and he's out of breath. Noticed breathing changes over the weekend. Urinating around house for the last week which he never normally does and it was very concentrated and very dark with foam and he does have diarrhea. He is also throwing up bile as of yesterday. He hasn't been eating and has been eating less and less over the last week with his last food being dog food last night and he's only drinking water at this point. Loves treats but wants nothing to do with them today and also refusing to play with toys which is extremely unusual. No c/s. Previously on very high protein diet because he was a police dog, they took him off that since he retired 2020. O is worried his kidneys may not be filtering well. Rads approved, ultrasound approved Questions: What is your pet's birth date or approx. age: 10 Is your pet on any medications (Vitamins, supplements): No medications When did your pet last get medications (If applicable): na Has your pet been vaccinated in the last 1-3 years: Yes: Who is your primary veterinarian/clinic? Ogden Animal Hospital Has your pet traveled outside Utah within the last year: No Does your pet have any other current medical problems: No Is your pet indoor, outdoor, or both: Both What is your pet fed: Instinct Dog Food 2/9/22 CREA 2.1 mg/dL 0.5 1.8 = BUN 34



PATIENT

mg/dL 7 27 = BUN/CREA 16 = ALT 34 U/L 10 125 = AST 55 U/L 0 50 = ALKP 256 U/L 23 212 =
Na 154 mmol/L 144 160 = K 3.8 mmol/L 3.5 5.8 = Na/K 41 = Cl 120 mmol/L 109 122 =

Havoc Caygle

COMPUTED TOMOGRAPHY OF THE THORAX

SPECIES

A high resolution pre- and post-contrast CT study of the thorax is provided for review.

Canine

COMPUTED TOMOGRAPHIC FINDINGS

The bony and surrounding soft tissue structures are within normal limits.

BREED

Belgian Sheperd

A mild amount of gravity dependent, non-contrast enhancing soft tissue material is visible in the pleural cavity. The ventral aspects of the lung lobes are retracted from the thoracic wall and pleural fissure lines are visible.

SEX

M

The sternal, cranial mediastinal and tracheobronchial lymph nodes are small elongated with a normal short-to-long-axis-ratio is < 0.5, the attenuation and contrast enhancement pattern is uniform and considered within normal limits.

AGE

10

The cardiovascular structures including the pulmonary vasculature are within normal limits.

The bronchial tree presents with regular branching and tapers uniformly towards the periphery as expected, the bronchial walls are thin and smooth. The bronchus-to-artery ratio is within normal limits.

INTERPRETED BY

Sebastian Schaub, DVM
Dr. med. vet. DipECVDI

The lung parenchyma presents the expected architecture and attenuation behavior.

Small incidental gas pockets are seen within the esophageal lumen, there is no evidence of abnormal dilation.

HOSPITAL NAME

Mountain West
Veterinary Hospital

The retroperitoneal fat surrounding the left kidney presents mild fat-stranding. The volume of the left kidney is moderately increased. The renal pelvis of the left kidney is moderately dilated. Post contrast administration no contrast excretion by the left kidney is appreciated. The left ureter is moderately dilated.

REFERRING VET

Jeff Simmons

COMPUTED TOMOGRAPHIC DIAGNOSIS

- Left sided pyelectasia, renal swelling and mild retroperitoneal effusion
- Left sided mild hydroureter, no mineral attenuating material is appreciated throughout the left ureter
- Lack of contrast excretion by the left kidney
- Mild pleural effusion

INVOICE

50193

INTERPRETATION OF THE FINDINGS & FURTHER RECOMMENDATIONS

DATE

2-9-22

There is evidence of mild pleural effusion and potentials are exudate versus transudate. A specific intrathoracic cause for the pleural effusion is not appreciated. The only mild contrast enhancement of the vascular system is limiting the diagnostic sensitivity to screen for intravascular thrombi formation (e.g. PTE) as cause for the acute dyspnea, but there are no signs for pulmonary hypoperfusion – a cardiac echo might be used to rule out signs for pulmonary hypertension completely. Recommend tapping the pleural effusion for further workup as well.



PATIENT

Havoc Caygle

The left renal pelvis is moderately dilated and there is generalized swelling of the left kidney and ureteral dilation. A specific cause cannot be appreciated. Rule out inflammatory causes such as pyelonephritis & ureteritis, mechanical obstruction (e.g. mass, stricture, protein plug) or subclinical ureteral ectopia.

SPECIES

Canine

BREED

Belgian Sheperd

SEX

M

AGE

10

INTERPRETED BY

Sebastian Schaub, DVM
Dr. med. vet. DipECVDI

HOSPITAL NAME

Mountain West
Veterinary Hospital

REFERRING VET

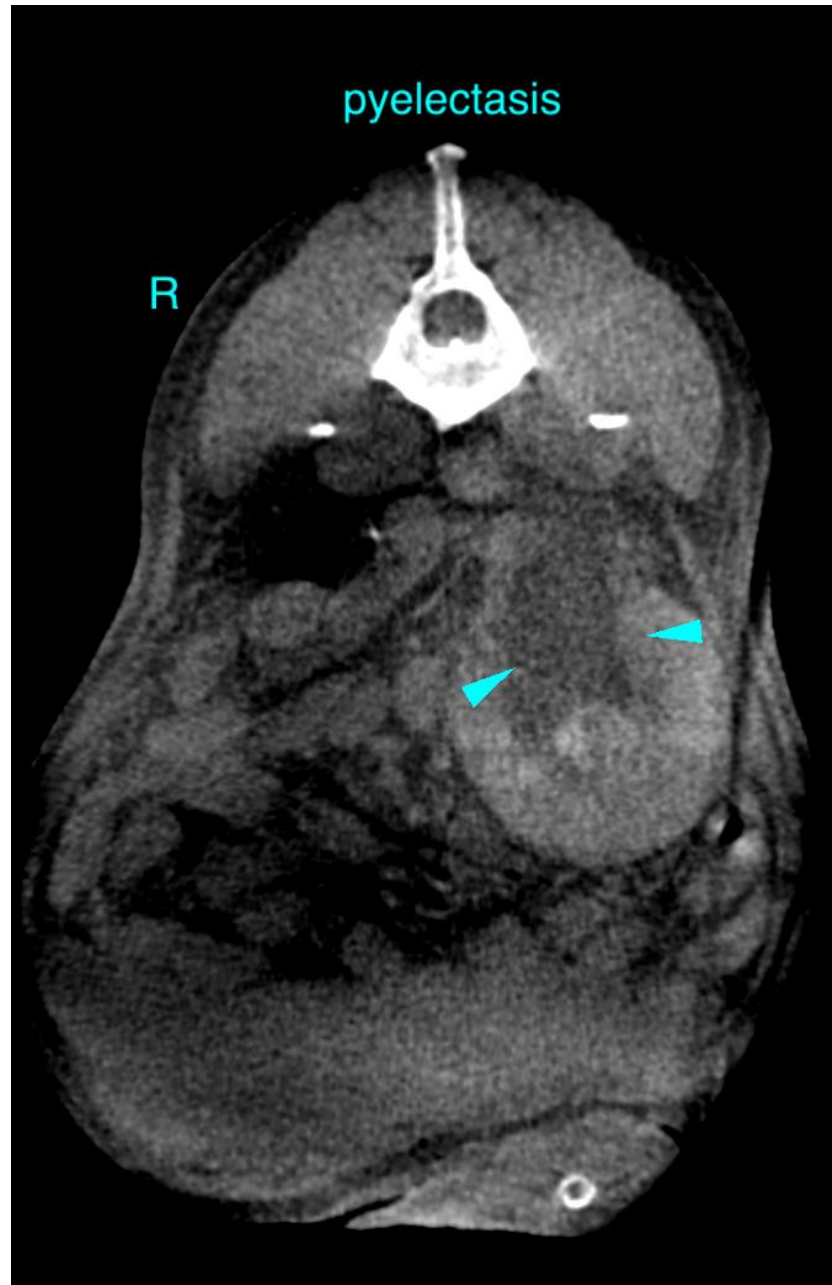Jeff Simmons

INVOICE

50193

DATE

2-9-22





PATIENT

Havoc Caygle

SPECIES

Canine

BREED

Belgian Sheperd

SEX

M

AGE

10

INTERPRETED BY

Sebastian Schaub, DVM
Dr. med. vet. DipECVDI

HOSPITAL NAME

Mountain West
Veterinary Hospital

REFERRING VET

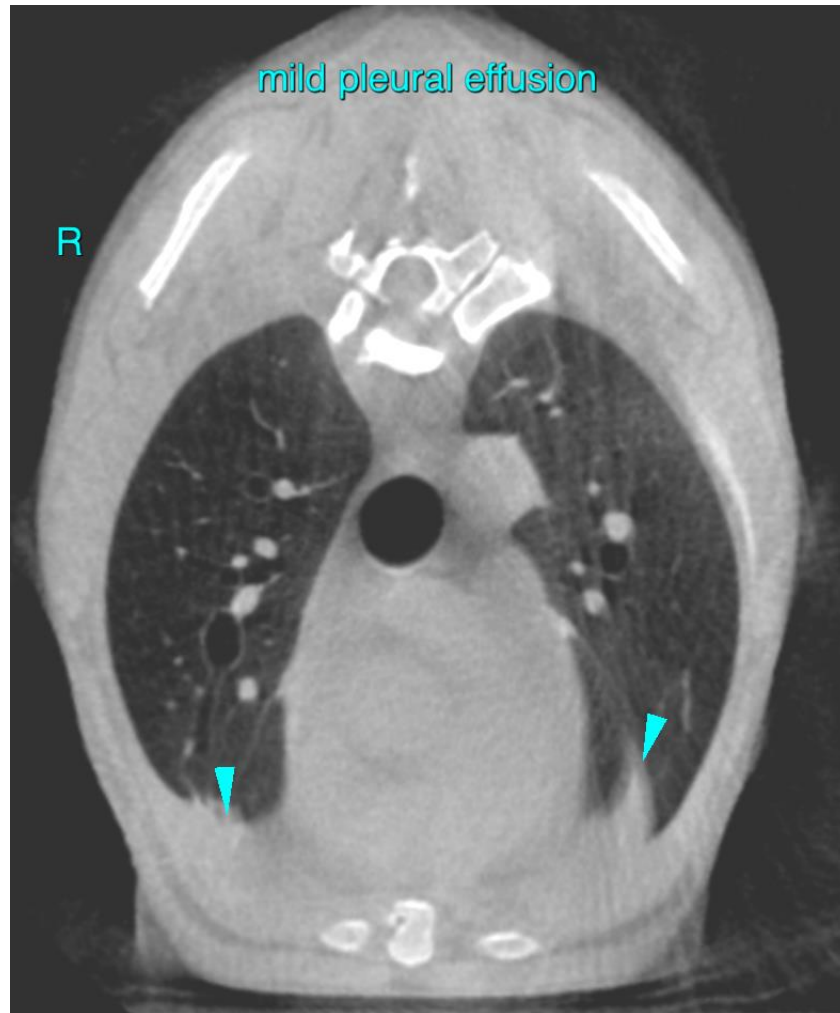
Jeff Simmons

INVOICE

50193

DATE

2-9-22



The information and recommendations provided are based on the images presented by the referring veterinarian/sonographer. No evaluation can be communicated regarding pathology that was not visible in the image/video clips provided.

Thank you for this referral. If the clinical or image interpretation does not parallel your findings or if I can be of any further assistance please contact me.

Sebastian Schaub, Sebastian Schaub, DVM, Dr. med. vet. DipECVDI
sebast.schaub@gmail.com