



PATIENT

Channel Morales

SPECIES

Female

BREED

Mixed

SEX

Female

AGE

6

WEIGHT

31

INTERPRETED BY

Sebastian Schaub, DVM
Dr. med. vet. DipECVCI

IMAGING PERFORMED BY

JD Veterinary Image
Center

HOSPITAL NAME

Juana Diaz AH

REFERRING VET

Jose Rivera, DVM

INVOICE

36774

DATE

2/8/26

PRESENTING CLINICAL SIGNS

- Referred for CT Imaging due to an apparent right maxillary region swelling that has been an on and off problem for the patient. Dental scaling was performed but no extractions were performed. No evidence of abscess on dental radiographs and COHAT evaluation.
- Abnormal PE/Chem/CBC/UA Results: WNL

COMPUTED TOMOGRAPHIC STUDY OF THE SKULL

A plain CT study of the skull in a bone and soft tissue reconstruction is provided for review.

COMPUTED TOMOGRAPHIC FINDINGS

ELECTRONIC IMAGE MARKERS ARE CONSIDERED TO BE FLIPPED – PATIENT POSITIONING IS SET TO 'HEAD FIRST SUPINE' BUT THE PATIENT IS IN VENTRAL RECUMBENCY.

The pictured parts of the dentition are complete. Triadan 109 presents moderate ill-defined periapical widening of the periodontal space; the lateral cortex of the alveolar crest of the mesial root is perforated. Level with triadan 108-109 a diffuse subcutaneous soft tissue swelling is appreciated.

The nasal cavity presents the expected aerated spaces between thin & even conchae and turbinates with smooth mucosal lining.

Both temporomandibular joints present congruent joint spaces with even subchondral bone surfaces and are considered within normal limits.

Both tympanic bullae are aerated, the mucosal lining is not seen, the bony wall is smooth and thin. The external ear canals are within normal limits.

The brain presents no deviation from normal anatomy and symmetry. The brain parenchyma is homogeneous and within normal limits for attenuation. The ventricular system is non-dilated and symmetric.

The lateral of the right mandibular lymph node is prominent.

COMPUTED TOMOGRAPHIC DIAGNOSIS

- Periapical abscess formation triadan 109 with fistula formation and accompanying subcutaneous soft tissue swelling
- Lymphadenopathy of a right mandibular lymph node – consistent with secondary reactive lymphoid hyperplasia

INTERPRETATION OF THE FINDINGS & FURTHER RECOMMENDATIONS

The clinically appreciated swelling in the right maxillary region is considered as a sequela to dental fistula of triadan 109. Extraction of the affected teeth is advised.



PATIENT

Channel Morales

SPECIES

Female

BREED

Mixed

SEX

Female

AGE

6

WEIGHT

31

INTERPRETED BY

Sebastian Schaub, DVM
Dr. med. vet. DipECVDI

IMAGING PERFORMED BY

JD Veterinary Image
Center

HOSPITAL NAME

Juana Diaz AH

REFERRING VET

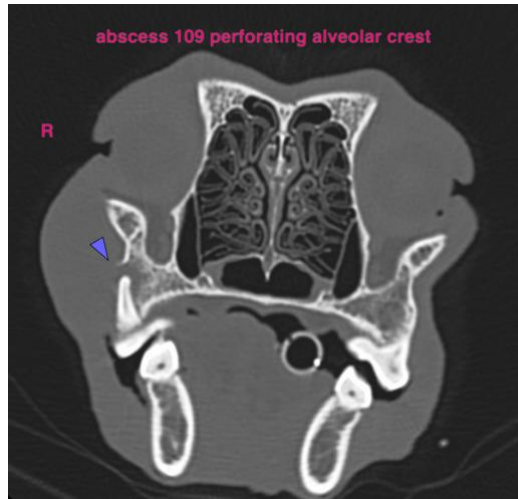
Jose Rivera, DVM

INVOICE

36774

DATE

2/8/26



The information and recommendations provided are based on the images presented by the referring veterinarian/sonographer. No evaluation can be communicated regarding pathology that was not visible in the image/video clips provided.

Thank you for this referral. If the clinical or image interpretation does not parallel your findings or if I can be of any further assistance please contact me.

Sebastian Schaub, DVM, Dr. med. vet. DipECVDI
info@sonopath.com