



**PATIENT**

Bernice Scafani

**PRESENTING CLINICAL SIGNS**

Presented on urgent care at another practice 1/28/23 due to vestibular signs (mild head tilt to the left and rotary nystagmus). A fleshy mass was noticed in the left nostril at that time. Mass has been enlarging over the past few weeks.

**SPECIES**

Canine

Abnormal PE/Chem/CBC/UA Results: intranasal mass occluding the left nostril. Mild hyperproteinemia and ALT elevation (140 U/L) on chemistry 1/23/23, NSF otherwise

**COMPUTED TOMOGRAPHY OF THE SKULL**

A high resolution pre- and post-contrast CT study of the skull is provided for review.

**BREED**

Pekingese

**COMPUTED TOMOGRAPHIC FINDINGS**

The tooth elements 101, 105, 201, 205, 206, 210, 301, 302, 305, 311, 401, 402, 406, 410 and 411 are absent. The remaining teeth present evidence of generalized moderate periodontal disease. Triadan 309 presents a significant widening of the periodontal space.

**SEX**

FS

Originating from the septum of the nasal planum, an ill-defined, uniform soft tissue attenuating and post contrast mild heterogeneous contrast enhancing intramural mass is seen, protruding into the left nasal opening; measuring 10 x 17 x 16 mm in size. A small amount of fluid attenuating material is attached to the nasal mucosal lining.

**AGE**

12 Years, 11 Months

Both temporomandibular joints present congruent joint spaces with even subchondral bone surfaces and are considered within normal limits.

**INTERPRETED BY**

Sebastian Schaub, DVM  
Dr. med. vet. DipECVDI

The left tympanic bulla is filled with a moderate amount of fluid attenuating material. The external ear canals are within normal limits. In the subcutaneous tissue at the caudal aspect of the base of the left pinna, a well-defined uniform soft tissue attenuating nodule, measuring 7 mm in size is appreciated.

**HOSPITAL NAME**

Healing Spirit Animal  
Wellness

The brain presents no deviation from normal anatomy and symmetry. The brain parenchyma is homogeneous and within normal limits for attenuation and distribution of contrast enhancement. The ventricular system is non-dilated and symmetric.

The submandibular and medial retropharyngeal lymph nodes are small and elongated with a normal short-to-long-axis-ratio is < 0.5, the attenuation and contrast enhancement pattern is uniform.

**REFERRING VET**

Sarah Green

**COMPUTED TOMOGRAPHIC DIAGNOSIS**

- Intramural soft tissue mass most rostral segment of the nasal septum/nasal planum
- Mild rhinitis
- Generalized periodontal disease
- Non-specific subcutaneous nodule base of the left pinna
- Multiple absent teeth

**INVOICE**

56661

**INTERPRETATION OF THE FINDINGS & FURTHER RECOMMENDATIONS**

**DATE**

2-8-23

The intramural mass of the nasal planum/rostral segment of the nasal septum is most consistent with primary soft tissue neoplasia – such as melanoma, squamous cell carcinoma, round cell tumor. Theoretically FNA sampling ± biopsy can be used as advanced diagnostic test. The chances of surgical management or radiation therapy can be discussed with surgeon/oncologist, based on the results of the advanced diagnostic tests.



**PATIENT**

Consider full tumor staging.

Bernice Scafani

**SPECIES**

Canine

**BREED**

Pekingese

**SEX**

FS

**AGE**

12 Years, 11 Months

**INTERPRETED BY**

Sebastian Schaub, DVM  
Dr. med. vet. DipECVDI

**HOSPITAL NAME**

Healing Spirit Animal  
Wellness

**REFERRING VET**

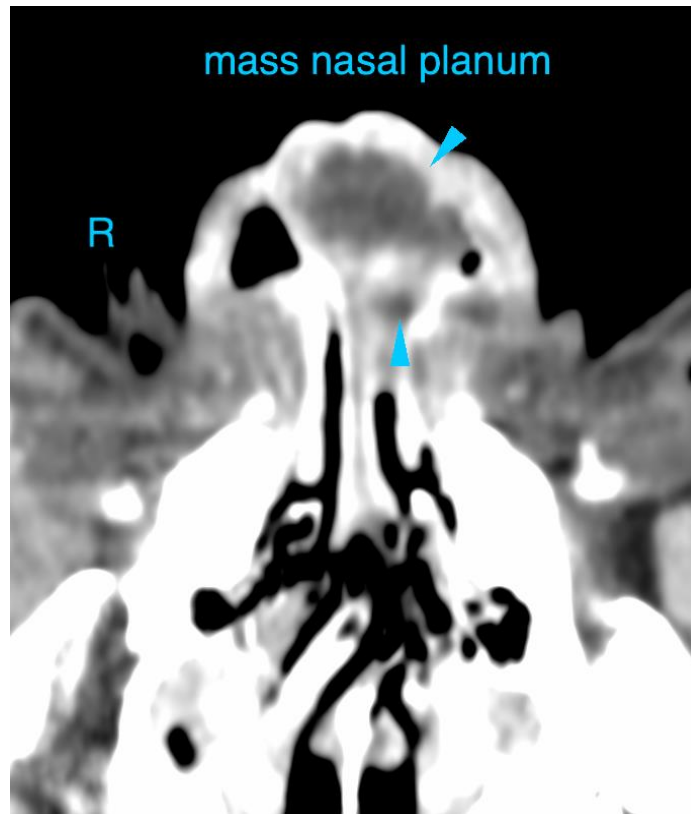
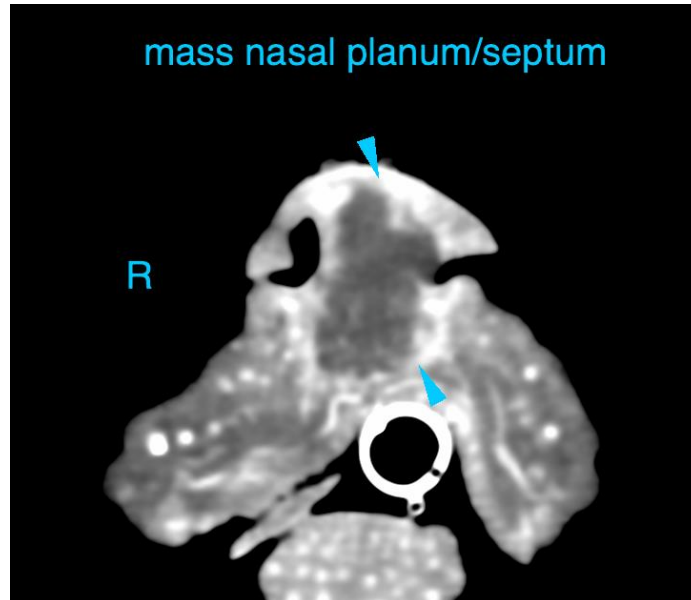
Sarah Green

**INVOICE**

56661

**DATE**

2-8-23





**PATIENT**

Bernice Scafani

The information and recommendations provided are based on the images presented by the referring veterinarian/sonographer. No evaluation can be communicated regarding pathology that was not visible in the image/video clips provided.

**SPECIES**

Canine

Thank you for this referral. If the clinical or image interpretation does not parallel your findings or if I can be of any further assistance please contact me.

**BREED**

Pekingese

**Sebastian Schaub**, Sebastian Schaub, DVM, Dr. med. vet. DipECVDI  
sebast.schaub@gmail.com

**SEX**

FS

**AGE**

12 Years, 11 Months

**INTERPRETED BY**

Sebastian Schaub, DVM  
Dr. med. vet. DipECVDI

**HOSPITAL NAME**

Healing Spirit Animal  
Wellness

**REFERRING VET**

Sarah Green

**INVOICE**

56661

**DATE**

2-8-23