

**PATIENT**

Shadow Garcia

PRESENTING CLINICAL SIGNS

Limping from right front paw history of elbow issues from previous rads o hasn't been giving the
dasuqin everyday
Abnormal PE/Chem/CBC/UA Results: cbc/chem/4Dx BUN 36.2 UA o to drop off

SPECIES

Canine

RADIOGRAPHIC STUDY OF THE CERVICAL SPINE & ELBOW JOINTS

Radiographs of the cervical spine and both front limbs in two orthogonal imaging planes.

BREED

Poodle

RADIOGRAPHIC FINDINGS

The intervertebral disc space C4/C5 is mildly narrowed. The remainder of the cervical spine are
within normal limits.

SEX

Male

The right and left elbow joints present smooth osseous margins, and no abnormalities of the
surrounding soft tissue structures are appreciated.

AGE

12 Years

RADIOGRAPHIC DIAGNOSIS

- Possible discopathy C4/C5
- Normal right and left elbow joints

INTERPRETATION OF THE FINDINGS & FURTHER RECOMMENDATIONS

The narrowing of the intervertebral disc space C4/C5 is suggestive for discopathy. Cross-
sectional imaging can be used to check for accompanying compressive myelopathy.

There is no pathology of the radiographs of the pictured elbow joints.

INTERPRETED BY

Sebastian Schaub, DVM
Dr. med. vet. DipECVDI

HOSPITAL NAME

Animal Paradise
Hospital

REFERRING VET

Dr. Kristen Hellwarth

INVOICE

50181

DATE

2-8-22



PATIENT

Shadow Garcia

SPECIES

Canine

BREED

Poodle

SEX

Male

AGE

12 Years

INTERPRETED BY

Sebastian Schaub, DVM
Dr. med. vet. DipECVDI

HOSPITAL NAME

Animal Paradise
Hospital

REFERRING VET

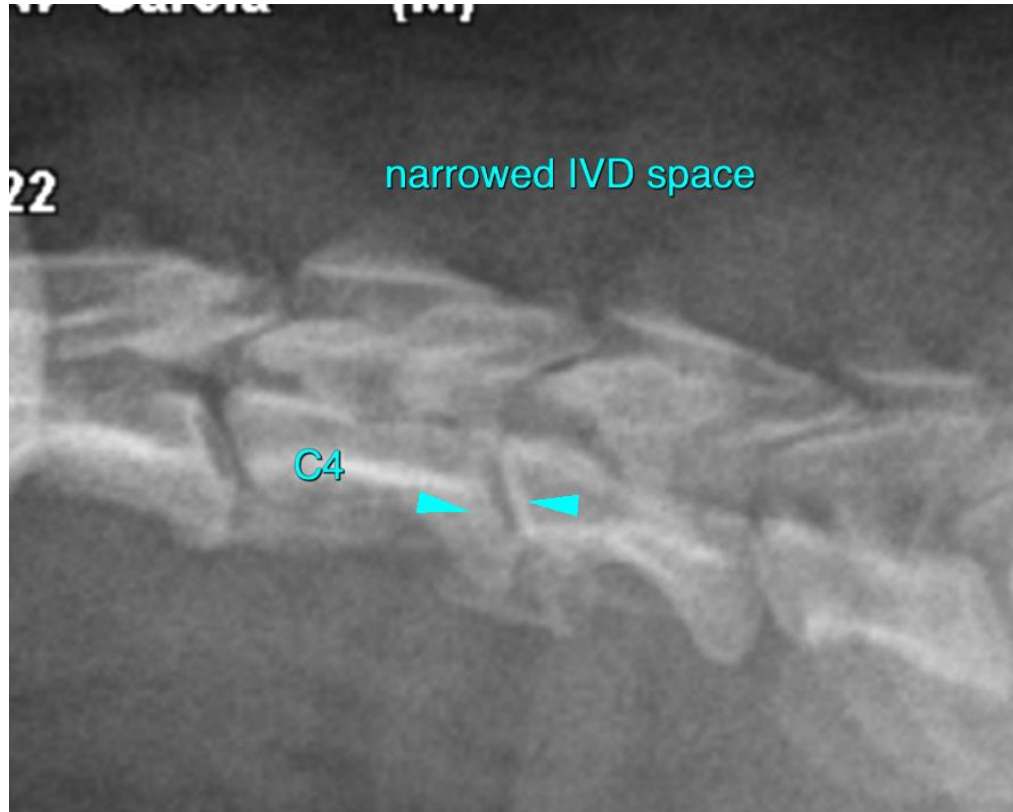
Dr. Kristen Hellwarth

INVOICE

50181

DATE

2-8-22



The information and recommendations provided are based on the images presented by the referring veterinarian/sonographer. No evaluation can be communicated regarding pathology that was not visible in the image/video clips provided.

Thank you for this referral. If the clinical or image interpretation does not parallel your findings or if I can be of any further assistance please contact me.

Sebastian Schaub, Sebastian Schaub, DVM, Dr. med. vet. DipECVDI
sebast.schaub@gmail.com