

**PATIENT**

Norman Romano

PRESENTING CLINICAL SIGNS

p presented for evaluation of cough. Started within last 24-36 hours. Has worsened. P was hospitalized for vomiting/diarrhea ~14 days ago. Concerned for aspiration pneumonia. Non-febrile.

SPECIES

Canine

RADIOGRAPHIC STUDY OF THE THORAX

Radiographs of the thorax in three imaging planes are provided for review.

BREED

Standard Poodle

RADIOGRAPHIC FINDINGS

The surrounding bony structures are within normal limits.

The extrathoracic soft tissues present homogeneous without abnormalities.

SEX

Neutered Male

The heart is of normal size and shape, there is no evidence of cardiac chamber or vascular enlargement. The pulmonary vasculature is within normal limits.

The esophagus is mildly dilated by gas.

AGE

2 Years

The trachea is normal in diameter and presents the anticipated course. The luminal outline of the trachea is smooth.

INTERPRETED BYSebastian Schaub, DVM
Dr. med. vet. DipECVDI

The right middle lung lobe presents a patchy soft tissue opacification, and the volume of the respective lung lobe is maintained. The left cranial lung lobe presents a mild to moderate ground glass opacification.

The diaphragm is well delineated with even surface and the expected mild cranial bulging of the diaphragmatic cupola.

HOSPITAL NAMEBelvedere Veterinary
Center**RADIOGRAPHIC DIAGNOSIS**

- Ventrally distributed alveolar pattern right middle lung lobe and mildly left cranial lung lobe
- Mild esophageal dilation

REFERRING VETBrendan Moulder
DVM**INTERPRETATION OF THE FINDINGS & FURTHER RECOMMENDATIONS**

The radiographic changes manifesting in the right middle lung lobe are compatible with bacterial pneumonia. Theoretically pulmonary hemorrhage or far less likely neoplastic infiltration are considerations. Recommend empirical management, follow up radiographs can be used to check regression of radiographic findings.

INVOICE

50172

The mild dilation of the esophagus can be secondary to aerophagia or esophagitis.

DATE

2-8-22



PATIENT

Norman Romano

SPECIES

Canine

BREED

Standard Poodle

SEX

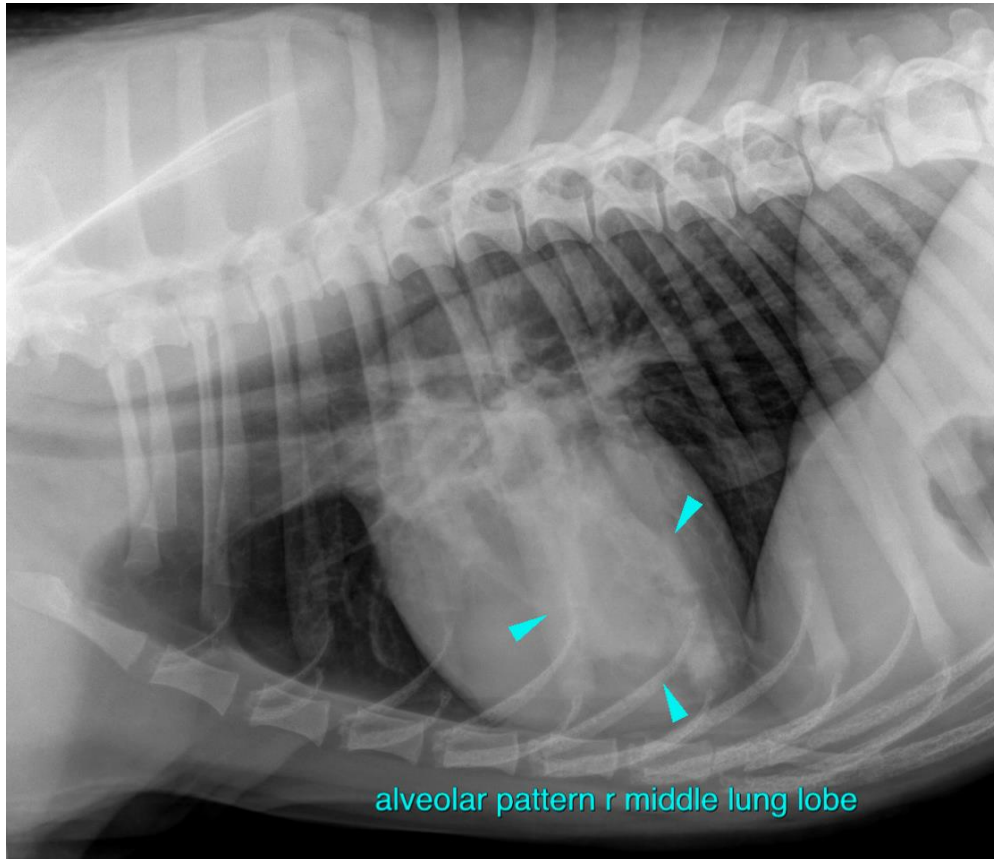
Neutered Male

AGE

2 Years

INTERPRETED BY

Sebastian Schaub, DVM
Dr. med. vet. DipECVDI



HOSPITAL NAME

Belvedere Veterinary
Center

REFERRING VET

Brendan Moulder
DVM

INVOICE

50172

DATE

2-8-22

The information and recommendations provided are based on the images presented by the referring veterinarian/sonographer. No evaluation can be communicated regarding pathology that was not visible in the image/video clips provided.

Thank you for this referral. If the clinical or image interpretation does not parallel your findings or if I can be of any further assistance please contact me.

Sebastian Schaub, Sebastian Schaub, DVM, Dr. med. vet. DipECVDI
sebast.schaub@gmail.com