



PATIENT PRESENTING CLINICAL SIGNS

PATIENT Griffin Stien
 Griffin first presented on 1/17/22 for acute onset stumbling and suspected vision and hearing loss. The neurologic signs resolved over the course of 1 week. There are no neurologic signs now. He has a chronic history of renal disease. Abdominal ultrasound on 4/23/22 documented changes in the kidney consistent with renal dysplasia. Systolic blood pressure was measured on 1/17/22 at 118, 118 and 120 mmHg. Abdominal ultrasound on 1/17/22 shows numerous urinary bladder stones and a large number of stones within the left renal pelvis and left proximal ureter. The owner is now feeding a homemade renal diet. Appetite and activity are normal. He gets 200 ml of SQ fluids daily. There is no vomiting or diarrhea. He is not on any medication at this time.

SPECIES Canine
BREED King Charles Cavalier Spaniel
 Abnormal PE/Chem/CBC/UA Results: PE: Normal Lab: Blood work is dated 2/7/22. CBC - PCV = 47%, WBC = 11000, neutrophils = 7260, lymphocytes = 2530, monocytes = 330. Platelets = 143-448K, platelet clumping, adequate numbers are reported. Chemistry - BUN = 43, Creat = 2.8, lipase = 592, amylase = 1907, SDMA = 30 (0-14), all else is normal. UA - USG = 1.006, pH = 7.5, negative protein, RBC = 2-5/hpf, WBC = 2-5/hpf, 2+ epithelial cells, amorphous phosphate crystals, no bacteria seen. Ultrasonographic Findings: Urinary Tract: Both kidneys are reduced in size and have very irregular margins. The left kidney measures 40.5 mm and the right 40.1 mm. Renal corticomedullary differentiation poor and echogenicity normal. The right renal pelvis is mildly distended measuring 3.2 mm. There are no right sided kidney stones. The right ureter is not dilated and measures 1.4-1.9 mm in diameter. There is a large amount of mineralized material (stones) within the left renal pelvis and left proximal ureter. The mineralized area within the left proximal ureter measures 18.7 mm in length. There is an additional stone separate from the first measuring 6.9 mm in diameter. Stone material within the left renal pelvis and ureter measures 23.1 mm in length. The left renal pelvis is not dilated. The left ureter distal to the proximal ureteral stones measures 1.7-1.8 mm in diameter. There is a stone measuring 3.1 x 2.8 mm within the lumen of the distal ureter just proximal to the left ureteral orifice. The ureter just proximal to the stone measures 2.6 mm in diameter. The left distal ureter measure 1.7-1.8 mm. Urinary bladder walls are smooth and thin. There are no bladder polyps or masses. Multiple small urinary bladder stones are present, the largest measuring 3.4, 4.1 and 6.9 mm in diameter. There are also hundreds of tiny stones (sand). Stones have irregular margins. The prostate is small measuring 6.8 mm in diameter. There are no stones visualized within the urethra. Cystoscopy Findings: The lower urinary tract is imaged with a 7.8 Fr flexible video ureteroscope. Mucosa lining the urethra is smooth and pale pink. There is no evidence of a urethral mass, stones or strictures. Multiple larger stones and numerous tiny stones are visible within the bladder lumen. The stones are cream colored with a slight green hue and have very irregular margins similar to broken concrete or dried clay. Urinary bladder mucosa is smooth and pale pink. Mucosa is thin. There is no evidence of increased vascularity. Ureteral orifices are visualized in their normal positions and pulsatile normal appearing urine observed flowing from both sides. There are no bladder polyps or masses. The pelvic urethra is accessed through a temporary perineal urethrotomy. The perineum is shaved, scrubbed and draped. A 5 mm skin incision is made just ventral to the anus on the midline. A 16-gauge needle is placed into the pelvic urethra under ultrasound and endoscopic guidance. A .035" PTFE coated urological guide wire is passed through the needle into the urinary bladder. The needle is removed and the urethrotomy is dilated to 16 Fr using serial dilators. A 16 Fr peel-away vascular access catheter is placed. The bladder is imaged using a 2.7 mm cystoscope through the access catheter. All stones are removed using an Ellik evacuator through the urethral access catheter. The urethral catheter is removed. Lidocaine is infused into the urethra. A bupivacaine block is performed at the incision site. The incision is left to heal by second intention.

SEX CM
AGE 4.5 Years

INTERPRETED BY Sebastian Schaub, DVM
 Dr. med. vet. DipECVDI

HOSPITAL NAME VetMed Consultants

REFERRING VET Rebecca Conway

INVOICE 50189

DATE 2-8-22

COMPUTED TOMOGRAPHY OF THE ABDOMEN

A high resolution pre- and post-contrast CT study of the abdomen is provided for review.

**PATIENT**

Griffin Stien

SPECIES

Canine

BREEDKing Charles Cavalier
Spaniel**SEX**

CM

AGE

4.5 Years

INTERPRETED BYSebastian Schaub, DVM
Dr. med. vet. DipECVDI**HOSPITAL NAME**

VetMed Consultants

REFERRING VET

Rebecca Conway

INVOICE

50189

DATE

2-8-22

COMPUTED TOMOGRAPHIC FINDINGS

Both kidneys present a significantly decreased volume with irregular margins. The renal pelvis of the left kidney is occupied by a mild heterogeneous mineral attenuating calculus, measuring 2.0 x 1.4 x 2.2 cm in size; the calculus is extending up into the proximal ureteral segment. In the most distal segment of the left ureter just proximal to the vesicoureteral junction, a mild amount of irregular mild mineral attenuating material is appreciated. There is a small amount of fluid attenuating material surrounding the left kidney. The right renal pelvis is mildly dilated, measuring approximately 3 mm in width. Contrast can be seen in both ureters.

The adrenal glands are within normal limits for size, shape and organ architecture.

Both liver and spleen present with normal shape, even surface, uniformly attenuating parenchyma and homogeneous contrast enhancement, unremarkable.

The portal vein presents a normal order of its tributary veins and intrahepatic branching. No abnormal vessel is noted inside and outside of the liver parenchyma.

The pancreas is evenly contoured, the pancreatic parenchyma is homogeneous and presents uniform contrast enhancement.

The position, delineation, wall and content of the gastrointestinal tract are considered within normal limits throughout.

The bony and surrounding soft tissue structures reveal no abnormalities.

COMPUTED TOMOGRAPHIC DIAGNOSIS

- Advanced chronic nephropathy and secondary pyelectasia
- Left sided large nephrolith, extending up into the proximal ureteral segment
- Small ureterolith distal segment left ureter
- No evidence of portosystemic shunting, neither intra- nor extrahepatic

INTERPRETATION OF THE FINDINGS & FURTHER RECOMMENDATIONS

The renal changes are consistent with advanced chronic nephropathy – either primary inflammatory in origin or due to underlying renal dysplasia. A large nephrolith is appreciated in the left renal pelvis, extending up into the proximal ureteral segment. The material in the distal aspect of the left ureter has likely dislodged from the large calculus in the left renal pelvis and likely causes increased outflow resistance.



PATIENT

Griffin Stien

SPECIES

Canine

BREED

King Charles Cavalier
Spaniel

SEX

CM

AGE

4.5 Years

INTERPRETED BY

Sebastian Schaub, DVM
Dr. med. vet. DipECVDI

HOSPITAL NAME

VetMed Consultants

REFERRING VET

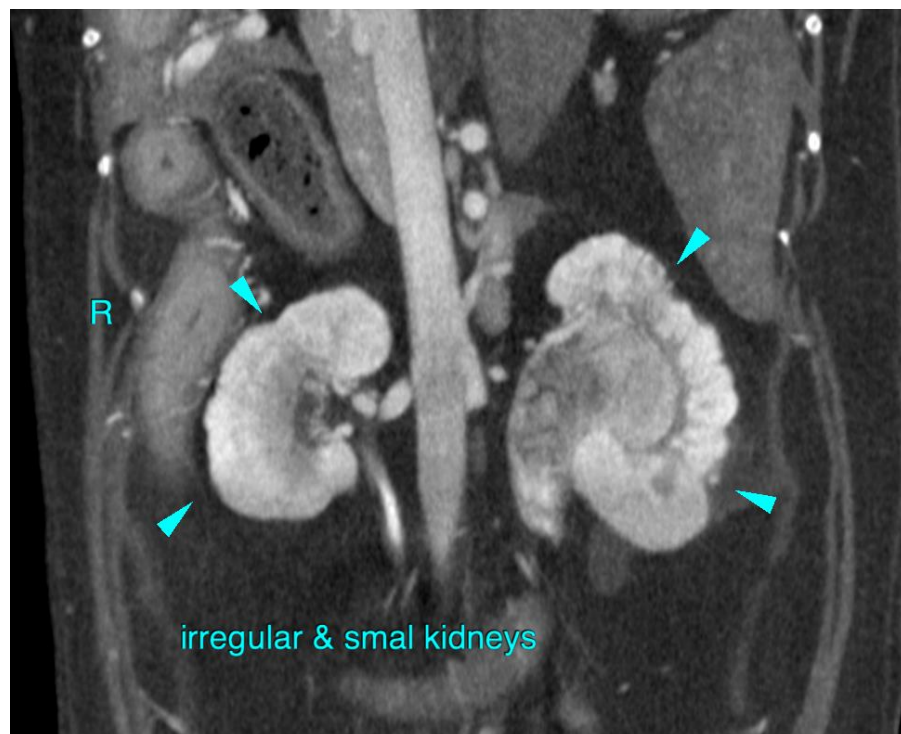
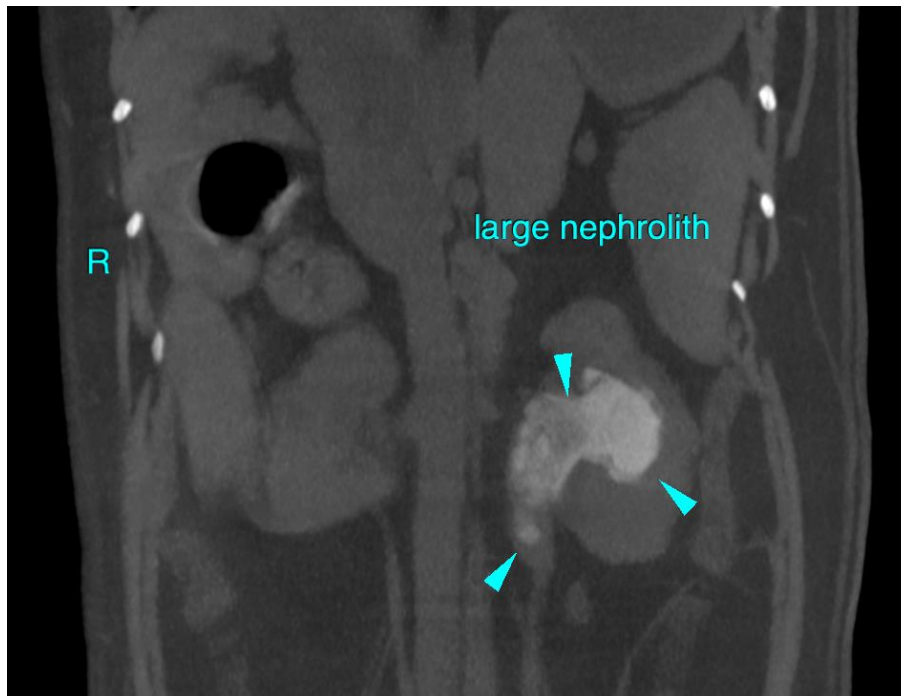
Rebecca Conway

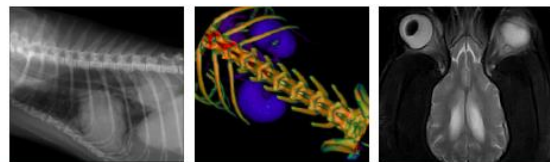
INVOICE

50189

DATE

2-8-22





PATIENT

Griffin Stien

SPECIES

Canine

BREED

King Charles Cavalier
Spaniel

SEX

CM

AGE

4.5 Years

INTERPRETED BY

Sebastian Schaub, DVM
Dr. med. vet. DipECVDI

HOSPITAL NAME

VetMed Consultants

REFERRING VET

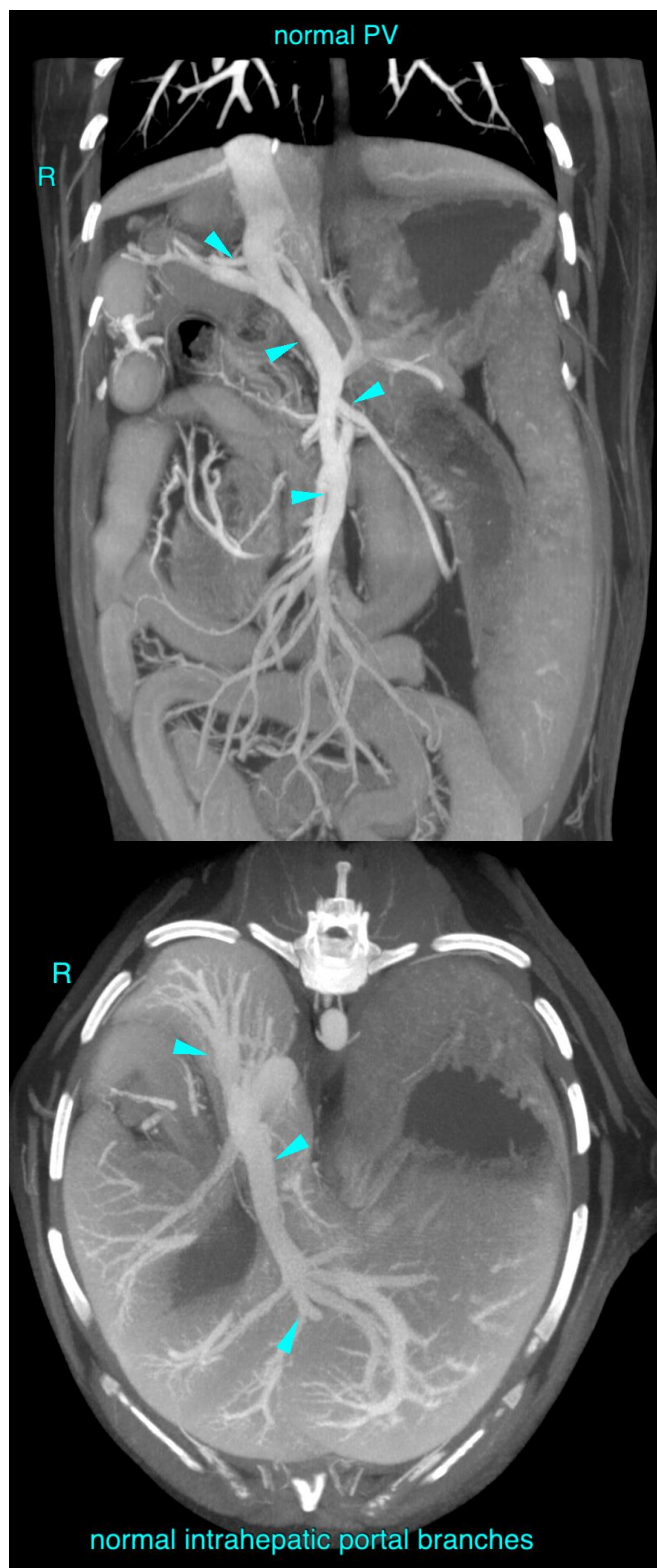
Rebecca Conway

INVOICE

50189

DATE

2-8-22





PATIENT

Griffin Stien

SPECIES

Canine

BREED

King Charles Cavalier
Spaniel

SEX

CM

AGE

4.5 Years

INTERPRETED BY

Sebastian Schaub, DVM
Dr. med. vet. DipECVDI

HOSPITAL NAME

VetMed Consultants

REFERRING VET

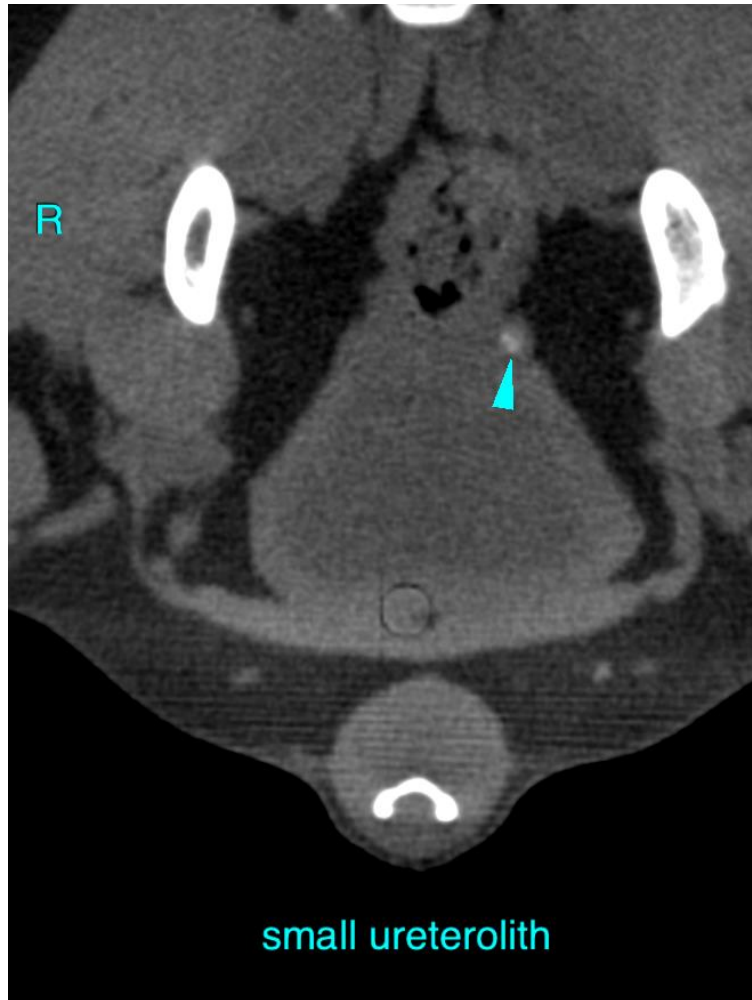
Rebecca Conway

INVOICE

50189

DATE

2-8-22



The information and recommendations provided are based on the images presented by the referring veterinarian/sonographer. No evaluation can be communicated regarding pathology that was not visible in the image/video clips provided.

Thank you for this referral. If the clinical or image interpretation does not parallel your findings or if I can be of any further assistance please contact me.

Sebastian Schaub, Sebastian Schaub, DVM, Dr. med. vet. DipECVDI
sebast.schaub@gmail.com