



PATIENT

Ruger Binstock

PRESENTING CLINICAL SIGNS

Chronic Hx of RF lameness; responds partially to NSAIDs and analgesics
 Abnormal PE/Chem/CBC/UA Results: Lamé at walk and trot RF; pain on R elbow manipulation

SPECIES

Canine

COMPUTED TOMOGRAPHY OF THE ELBOW JOINTS

A high resolution plain CT study of the elbow joints is provided for review.

BREED

Labrador

The periarticular bones of both elbow joints present mild to moderate osteophyte new bone formation, R>L.

SEX

MN

The medial coronoid process of the right elbow joint has an elongated hook shaped conformation and heterogeneous attenuation pattern. The tip of the medial coronoid process of the left elbow joint is irregular and has a decreased density. The medial compartment of the left elbow joint

At the medial aspect of the right medial humeral epicondyle, in the proximal aspect of the flexor muscles a roundish zone with mild irregular mineralization is appreciated.

AGE

9 Years, 7 Months

COMPUTED TOMOGRAPHIC DIAGNOSIS

- Coronoid disease elbow joints bilaterally
- Narrowed joint space medial compartment right elbow joint
- Advanced degenerate osteoarthritis elbow joints bilaterally
- Suspect flexor enthesopathy right elbow joint

INTERPRETED BY

Sebastian Schaub, DVM
 Dr. med. vet. DipECVDI

INTERPRETATION OF THE FINDINGS & FURTHER RECOMMENDATIONS

The findings are consistent with chronic degenerative joint disease of both elbow joints due pathology of the medial coronoid process. The narrowed medial compartment of the right elbow joint can indicate medial compartment syndrome with cartilage damage – possible explaining the pain.

HOSPITAL NAME

State Avenue Vet
 Clinic

Arthroscopy can be used revise the elbow joints. The appreciated degenerative changes are irreversible and will likely be progressive.

REFERRING VET

Dr Raul Casas-Dolz

INVOICE

56610

DATE

2-7-23



PATIENT

Ruger Binstock

SPECIES

Canine

BREED

Labrador

SEX

MN

AGE

9 Years, 7 Months

INTERPRETED BY

Sebastian Schaub, DVM
Dr. med. vet. DipECVDI

HOSPITAL NAME

State Avenue Vet
Clinic

REFERRING VET

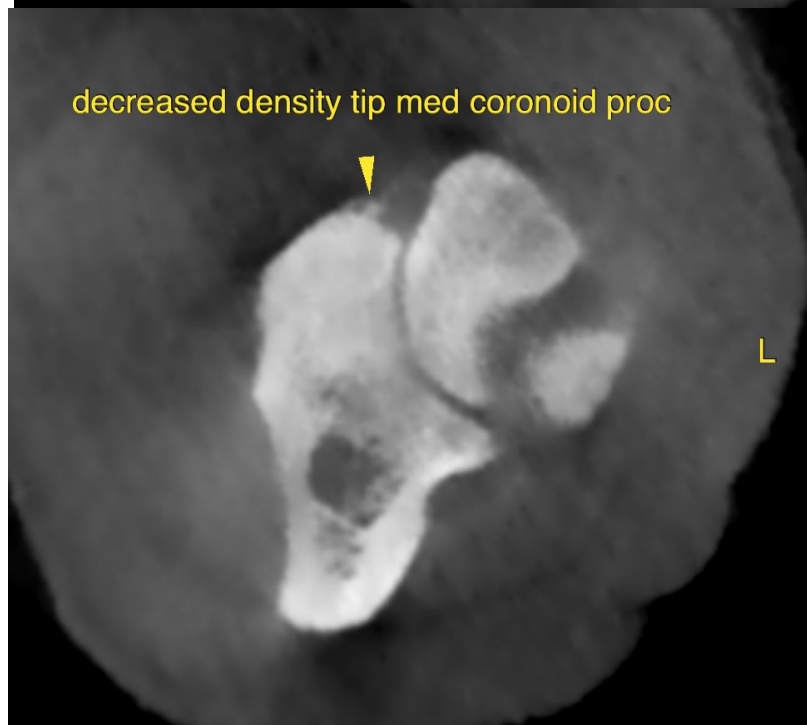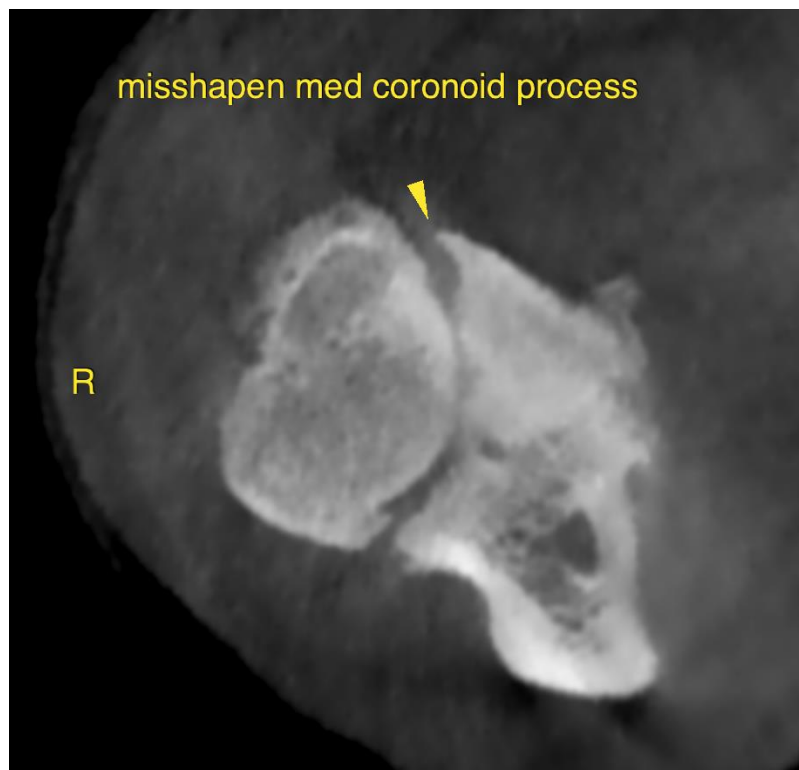
Dr Raul Casas-Dolz

INVOICE

56610

DATE

2-7-23





PATIENT

Ruger Binstock

SPECIES

Canine

BREED

Labrador

SEX

MN

AGE

9 Years, 7 Months

INTERPRETED BY

Sebastian Schaub, DVM
Dr. med. vet. DipECVDI

HOSPITAL NAME

State Avenue Vet
Clinic

REFERRING VET

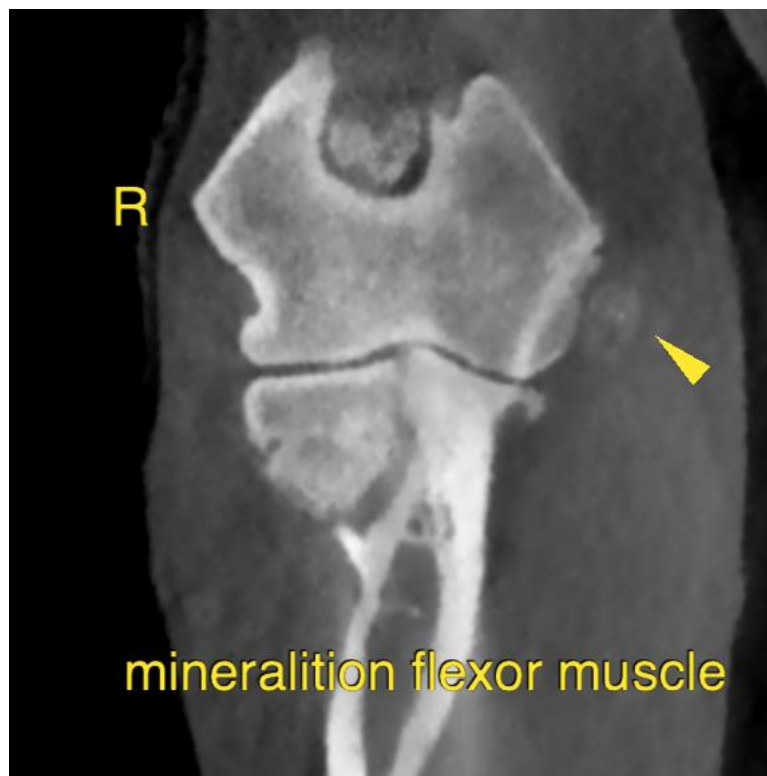
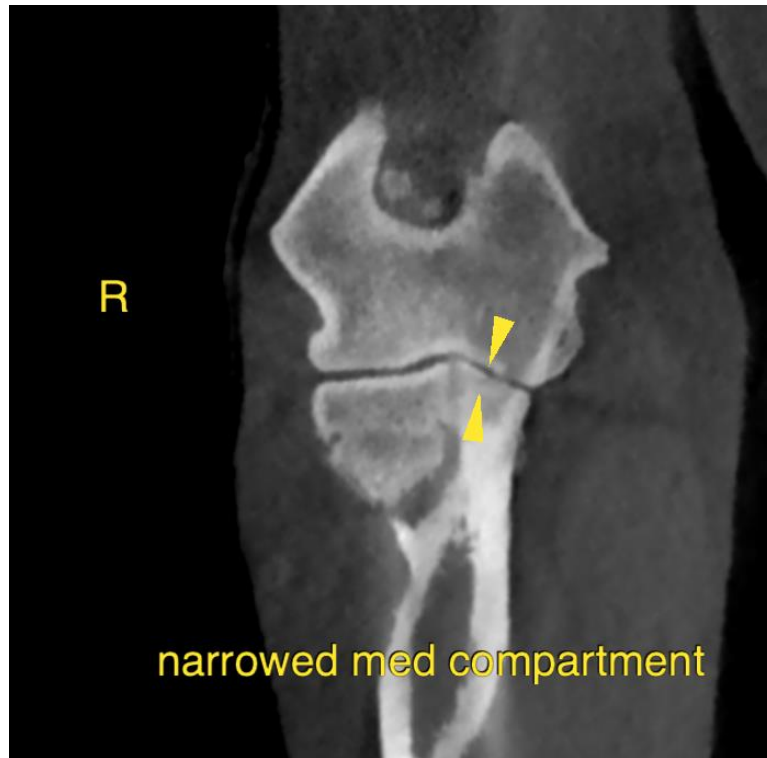
Dr Raul Casas-Dolz

INVOICE

56610

DATE

2-7-23





PATIENT

Ruger Binstock

The information and recommendations provided are based on the images presented by the referring veterinarian/sonographer. No evaluation can be communicated regarding pathology that was not visible in the image/video clips provided.

SPECIES

Canine

Thank you for this referral. If the clinical or image interpretation does not parallel your findings or if I can be of any further assistance please contact me.

BREED

Labrador

Sebastian Schaub, Sebastian Schaub, DVM, Dr. med. vet. DipECVDI
sebast.schaub@gmail.com

SEX

MN

AGE

9 Years, 7 Months

INTERPRETED BY

Sebastian Schaub, DVM
Dr. med. vet. DipECVDI

HOSPITAL NAME

State Avenue Vet
Clinic

REFERRING VET

Dr Raul Casas-Dolz

INVOICE

56610

DATE

2-7-23