



PATIENT

Napo Montañez

SPECIES

Canine

BREED

Pitbull Mix

SEX

NM

AGE

7 Years

INTERPRETED BY

Sebastian Schaub, DVM
Dr. med. vet. DipECVDI

HOSPITAL NAME

Veterinary Image
Center

REFERRING VET

Dr. F. Piñero, DVM

INVOICE

56606

DATE

2-7-23

PRESENTING CLINICAL SIGNS

Recurrent pain on the neck responsive to treatment for a few weeks. Pain mostly on flexion. Slow on proprioception but placement noted. Questionable IV radiodensity on C4-C5 and C5-C6. Has been offered RC Satiety and has successfully lost 9.0 lbs in the last 2 months. Medication:

Prednisone 20mg: 2 tab PO BID x5d, then 1 tab BID x5d

Abnormal PE/Chem/CBC/UA Results: CBC --- mild neutrophilia CHEM --- ALT and ALKP mild increased

COMPUTED TOMOGRAPHY OF THE CERVICAL SPINE

A high resolution pre- and post-contrast CT study of the cervical spine is provided for review.

COMPUTED TOMOGRAPHIC FINDINGS

Level with the intervertebral disc space C2/C3, heterogeneous mild mineral attenuating material is seen in the left ventral aspect of the vertebral canal, occupying approximately 20% of the cross-sectional area of the vertebral canal at the same level. The dural tube level C2/C3 is deviated dorsally and distorted by the mass effect. The vertebral endplates C2/C3 present mild ventral spondylosis formation.

Central mineralization of the intervertebral disc C5/C6 is noted.

Level with the intervertebral disc space C6/C7 mild hyperattenuating material is mildly bulging into the vertebral canal, distorting the ventral epidural space.

COMPUTED TOMOGRAPHIC DIAGNOSIS

- Intervertebral disc extrusion C2/C3 with compressive myelopathy
- Mild intervertebral disc protrusion C6/C7 without compressive myelopathy
- Chondroid disc degeneration C5/C6
- Spondylosis deformans

INTERPRETATION OF THE FINDINGS & FURTHER RECOMMENDATIONS

The intervertebral disc extrusion level C2/C3 is a potential cause for the described cervical pain and surgical decompression might be considered if clinical signs are refractory to empirical conservative management.



PATIENT

Napo Montañez

SPECIES

Canine

BREED

Pitbull Mix

SEX

NM

AGE

7 Years

INTERPRETED BY

Sebastian Schaub, DVM
Dr. med. vet. DipECVDI

HOSPITAL NAME

Veterinary Image
Center

REFERRING VET

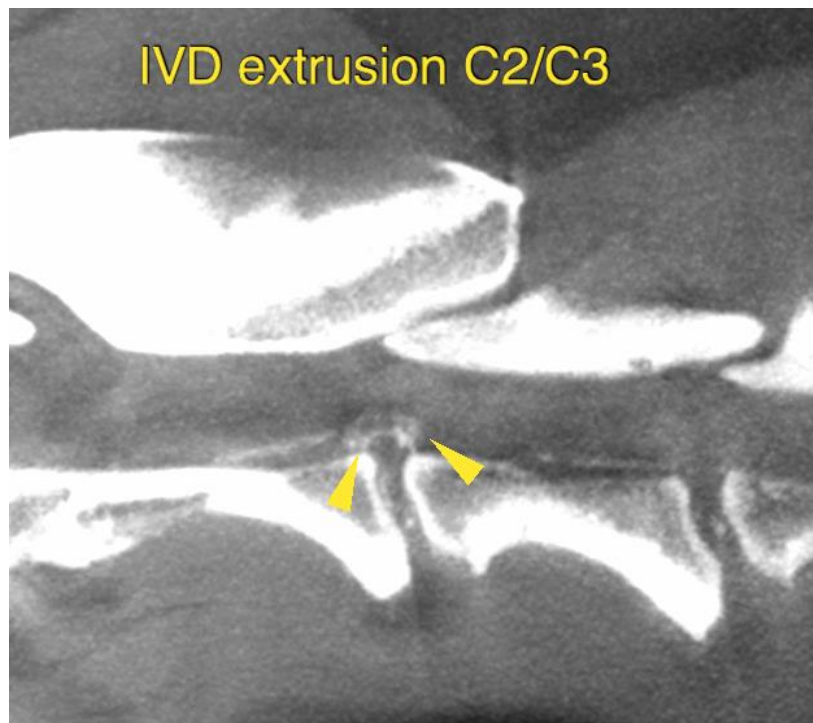
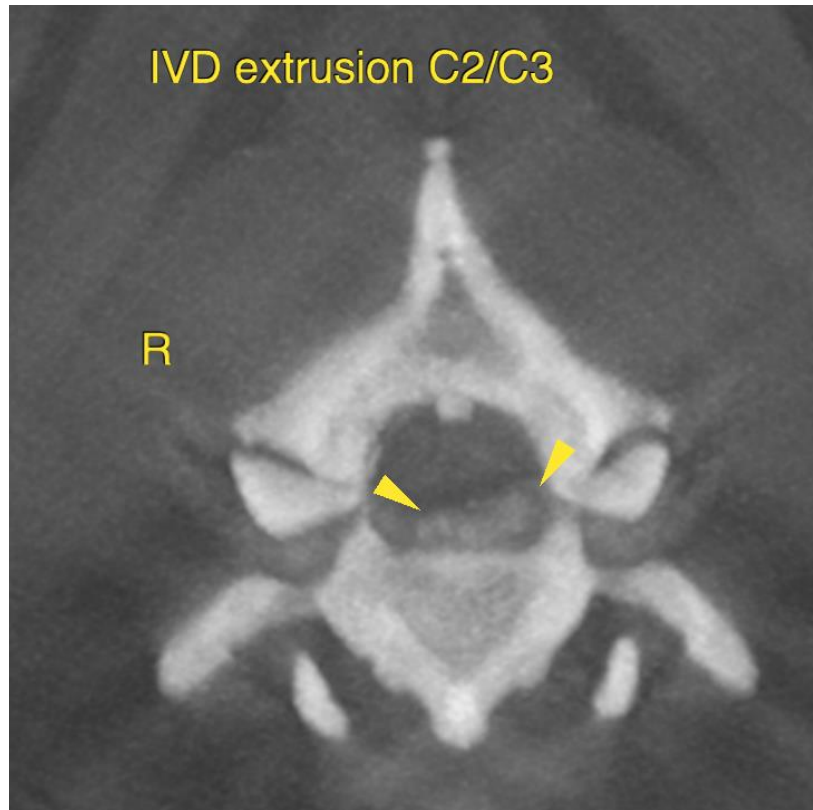
Dr. F. Piñero, DVM

INVOICE

56606

DATE

2-7-23





PATIENT

Napo Montañez

SPECIES

Canine

The information and recommendations provided are based on the images presented by the referring veterinarian/sonographer. No evaluation can be communicated regarding pathology that was not visible in the image/video clips provided.

BREED

Pitbull Mix

Thank you for this referral. If the clinical or image interpretation does not parallel your findings or if I can be of any further assistance please contact me.

Sebastian Schaub, Sebastian Schaub, DVM, Dr. med. vet. DipECVDI
sebast.schaub@gmail.com

SEX

NM

AGE

7 Years

INTERPRETED BY

Sebastian Schaub, DVM
Dr. med. vet. DipECVDI

HOSPITAL NAME

Veterinary Image
Center

REFERRING VET

Dr. F. Piñero, DVM

INVOICE

56606

DATE

2-7-23