



**PATIENT**

Calypso Diaz

**PRESENTING CLINICAL SIGNS**

O has had her since Thanksgiving, no history of vet care, no vaccines. Accidental litter from a family member. No history of illness. Sunday she tripped getting out of the truck and has been nonweightbearing in the right hind leg since then. No significant swelling was noted. Normal appetite and attitude

**SPECIES**

Canine

Abnormal PE/Chem/CBC/UA Results: Oral cavity: permanent incisors, permanent canines starting to erupt, deciduous premolars and caudal. No dental tartar. Musculoskeletal: BCS = normal juvenile. toe-touching right hind, palpable displacement of the proximal tibia/tibial crest, painful on stifle flexion, unable to get into full extension

**BREED**

Pitbull

**RADIOGRAPHIC STUDY OF THE STIFLE JOINTS**

Radiographs of both stifle joints in two orthogonal imaging planes are provided for review.

**SEX**

Female

**RADIOGRAPHIC FINDINGS**

The growth plates are age related open.

The osseous and soft tissue structures of the left stifle joint present without abnormalities.

**AGE**

4 Months, 1 Week

The tibial tuberosity is avulsed from the right tibia and rotated proximally. Multiple irregular mineralization are appreciated within the markedly widened growth plate of the right tibial tuberosity. A mild to moderate homogeneous soft tissue swelling is seen at the cranial aspect of the tibial tuberosity. The epiphysis of the right tibia is unremarkable.

**INTERPRETED BY**

Sebastian Schaub, DVM  
Dr. med. vet. DipECVDI

**RADIOGRAPHIC DIAGNOSIS**

- Right sided avulsion fracture of the right tibial tuberosity with possible small avulsion fragments

**HOSPITAL NAME**

DPC Veterinary Hospital

**INTERPRETATION OF THE FINDINGS & FURTHER RECOMMENDATIONS**

The radiographic study is consistent with subacute avulsion fracture of the right tibial tuberosity. The mineralized bodies along the widened apophysis of the right tibial tuberosity can present small avulsion fragments or indicate subacute to chronic status – considered less likely due to the acute history with trauma on Sunday. Surgical management is advised.

**REFERRING VET**

Cepero

**INVOICE**

56608

**DATE**

2-7-23



**PATIENT**

Calypso Diaz

**SPECIES**

Canine

**BREED**

Pitbull

**SEX**

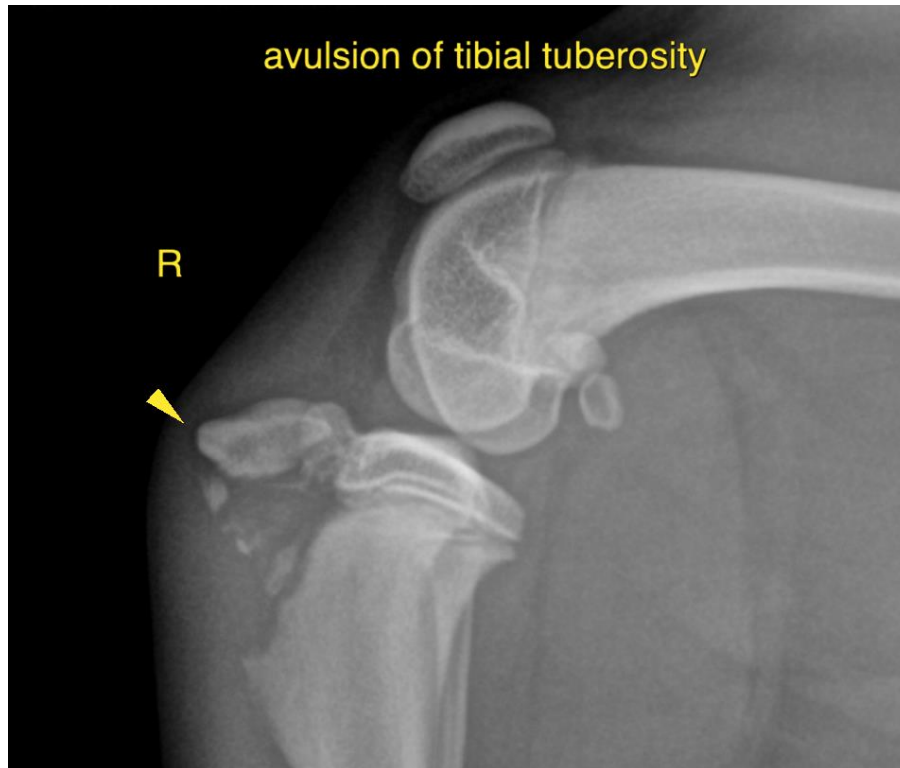
Female

**AGE**

4 Months, 1 Week

**INTERPRETED BY**

Sebastian Schaub, DVM  
Dr. med. vet. DipECVDI



**HOSPITAL NAME**

DPC Veterinary  
Hospital

**REFERRING VET**

Cepero

**INVOICE**

56608

**DATE**

2-7-23

The information and recommendations provided are based on the images presented by the referring veterinarian/sonographer. No evaluation can be communicated regarding pathology that was not visible in the image/video clips provided.

Thank you for this referral. If the clinical or image interpretation does not parallel your findings or if I can be of any further assistance please contact me.

**Sebastian Schaub**, Sebastian Schaub, DVM, Dr. med. vet. DipECVDI  
sebast.schaub@gmail.com