



PATIENT

Smoke Wiersma

PRESENTING CLINICAL SIGNS

acute diarrhea 2 days ago and lethargic
Abnormal PE/Chem/CBC/UA Results: BW is unremarkable

SPECIES

Feline

RADIOGRAPHIC STUDY OF THE ABDOMEN

Radiographs of the abdomen in two orthogonal imaging planes are provided for review.

BREED

DMH

RADIOGRAPHIC FINDINGS

The surrounding bony structures are within normal limits.

SEX

Male Neuter

No abnormalities of the extraabdominal soft tissues are noted. The abdominal wall is smooth and thin.

The serosal detail is maintained throughout the peritoneal and retroperitoneal space.

AGE

9 Months

The liver is appropriate in position, size and presents uniform opacity.

The splenic head is in the anticipated position and within normal limits for size and opacity. The splenic body and tail are considered normal for position, size, shape and opacity.

INTERPRETED BY

Sebastian Schaub, DVM
Dr. med. vet. DipECVDI

Both kidneys are seen and present with normal size, shape, delineation and opacity. The urinary bladder is in its anticipated position. No radiopaque calculi are noted throughout the upper and lower urinary tract.

The stomach is in its anticipated position and presents normal content.

HOSPITAL NAME

St. Catherine's Animal
Hospital

The small intestinal loops are of even diameter and non-dilated, a small amount of gas is seen within the small intestinal loops and considered within normal limits.

The colon is seen in the expected position and is empty. Level whit L4/L5 roundish soft tissue opacity is seen dorsal to the colon.

REFERRING VET

Dr. Masoud

RADIOGRAPHIC DIAGNOSIS

- Empty colon
- Suspect mild reactive hyperplasia of the colonic lymph node

INTERPRETATION OF THE FINDINGS & FURTHER RECOMMENDATIONS

INVOICE

50140

The empty colon is fitting the history of diarrhea. An underlying cause is not appreciated. There is no evidence of radiopaque foreign material or signs for gastrointestinal mechanical obstruction. The presumptive diagnosis is enteritis. Recommend empirical management. If clinical signs are refractory to therapy, recommend complete abdominal ultrasound examination. Complementing workup by a fecal examination appears beneficial as well.

DATE

2-7-22



PATIENT

Smoke Wiersma

SPECIES

Feline

BREED

DMH

SEX

Male Neuter

AGE

9 Months

INTERPRETED BY

Sebastian Schaub, DVM
Dr. med. vet. DipECVDI

HOSPITAL NAME

St. Catherine's Animal
Hospital

REFERRING VET

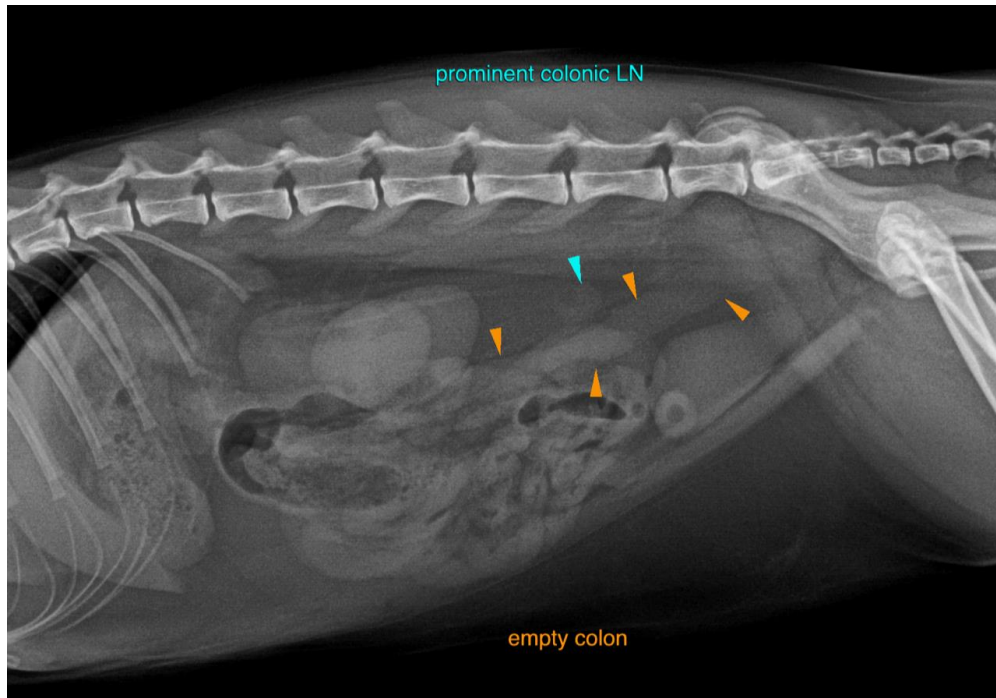
Dr. Masoud

INVOICE

50140

DATE

2-7-22



The information and recommendations provided are based on the images presented by the referring veterinarian/sonographer. No evaluation can be communicated regarding pathology that was not visible in the image/video clips provided.

Thank you for this referral. If the clinical or image interpretation does not parallel your findings or if I can be of any further assistance please contact me.

Sebastian Schaub, Sebastian Schaub, DVM, Dr. med. vet. DipECVDI
sebast.schaub@gmail.com