



PATIENT

Mochi Gomez

PRESENTING CLINICAL SIGNS

2 days ago P was playing with housemate and jumped off a bean bag chair and hurt the RHL. P yelps in pain and will walk on all 4s for short periods of time. O has been treating at home with ice (BID-TID)

SPECIES

Canine

RADIOGRAPHIC STUDY OF THE RIGHT STIFLE JOINT

Radiographs of the right stifle joint in two orthogonal imaging planes are provided for review.

BREED

Maltese

RADIOGRAPHIC FINDINGS

In the craniocaudal projection of the right stifle joint , the patella is superimposed on the soft tissues medial to the medial femoral condyle. The osseous margins of the right stifle joint are smooth.

SEX

Neutered Male

The growth plate between the tibial tuberosity and tibial metaphysis is still visible bilaterally.

AGE

12 Months

RADIOGRAPHIC DIAGNOSIS

- Right sided medial patellar luxation

INTERPRETATION OF THE FINDINGS & FURTHER RECOMMENDATIONS

The findings are consistent with right sided medial patellar luxation. The visible apophysis of the tibial tuberosity can still be a normal finding – should close at with 12 month of age.

INTERPRETED BY

Sebastian Schaub, DVM
Dr. med. vet. DipECVDI

HOSPITAL NAME

DPC Veterinary
Hospital

REFERRING VET

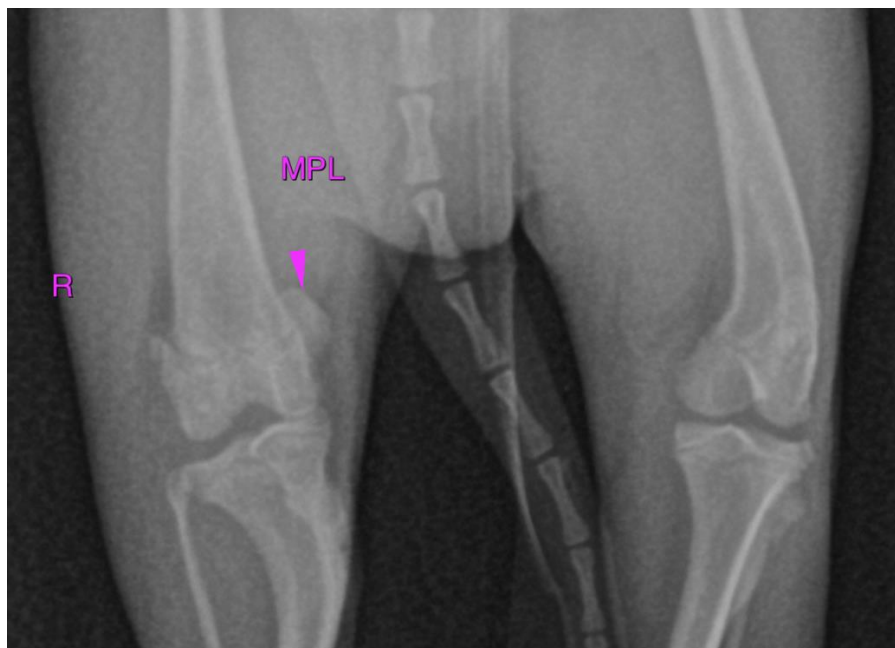
Dr. White

INVOICE

50138

DATE

2-7-22





PATIENT

Mochi Gomez

The information and recommendations provided are based on the images presented by the referring veterinarian/sonographer. No evaluation can be communicated regarding pathology that was not visible in the image/video clips provided.

SPECIES

Canine

Thank you for this referral. If the clinical or image interpretation does not parallel your findings or if I can be of any further assistance please contact me.

Sebastian Schaub, Sebastian Schaub, DVM, Dr. med. vet. DipECVDI
sebast.schaub@gmail.com

BREED

Maltese

SEX

Neutered Male

AGE

12 Months

INTERPRETED BY

Sebastian Schaub, DVM
Dr. med. vet. DipECVDI

HOSPITAL NAME

DPC Veterinary
Hospital

REFERRING VET

Dr. White

INVOICE

50138

DATE

2-7-22