



PATIENT

Lola Karanopoulos

PRESENTING CLINICAL SIGNS

Vomiting/choking on and off last few days. R/O tracheal collapse vs asthma vs other

SPECIES

Canine

RADIOGRAPHIC STUDY OF THE THORAX

Radiographs of the thorax in three imaging planes are provided for review.

BREED

Chihuahua

RADIOGRAPHIC FINDINGS

The surrounding bony structures are within normal limits.

At the left craniolateral thoracic wall, caudal to the left scapula, an ovoid shaped, fat opaque mass is visible, measuring approximately 5.9 x 1.9 cm in size.

SEX

Female

The heart is of normal size and shape, there is no evidence of cardiac chamber or vascular enlargement. The pulmonary vasculature is within normal limits.

The cranial mediastinum presents the expected soft tissue opacity. The mediastinal width is less than twice the width of the vertebral column at the same level.

AGE

22 Months

The trachea is normal in diameter and presents the anticipated course. The luminal outline of the trachea is smooth.

INTERPRETED BY

Sebastian Schaub, DVM
Dr. med. vet. DipECVDI

The bronchial tree presents with thin walls and tapers uniformly towards the periphery as expected.

The lung parenchyma presents the expected architecture and opacity; the intrapulmonary vascular branching is seen up to the third order lung vessels.

HOSPITAL NAME

Truscott Animal
Hospital

The diaphragm is well delineated with even surface and the expected mild cranial bulging of the diaphragmatic cupola.

RADIOGRAPHIC DIAGNOSIS

- Suspect lipoma left thoracic wall

REFERRING VET

Medhat Meawad

INTERPRETATION OF THE FINDINGS & FURTHER RECOMMENDATIONS

The radiographic study of the thorax presents without clinically relevant pathology. There are no signs for tracheal collapse or evidence of air-way infection. However, negative radiographs do not rule out possible inflammatory lower airway disease completely.

INVOICE

50141

TECHNICAL COMMENTS

Gloved hands are seen in the primary beam, please consider radiation safety guidelines!

DATE

2-7-22



PATIENT

Lola Karanopoulos

SPECIES

Canine

BREED

Chihuahua

SEX

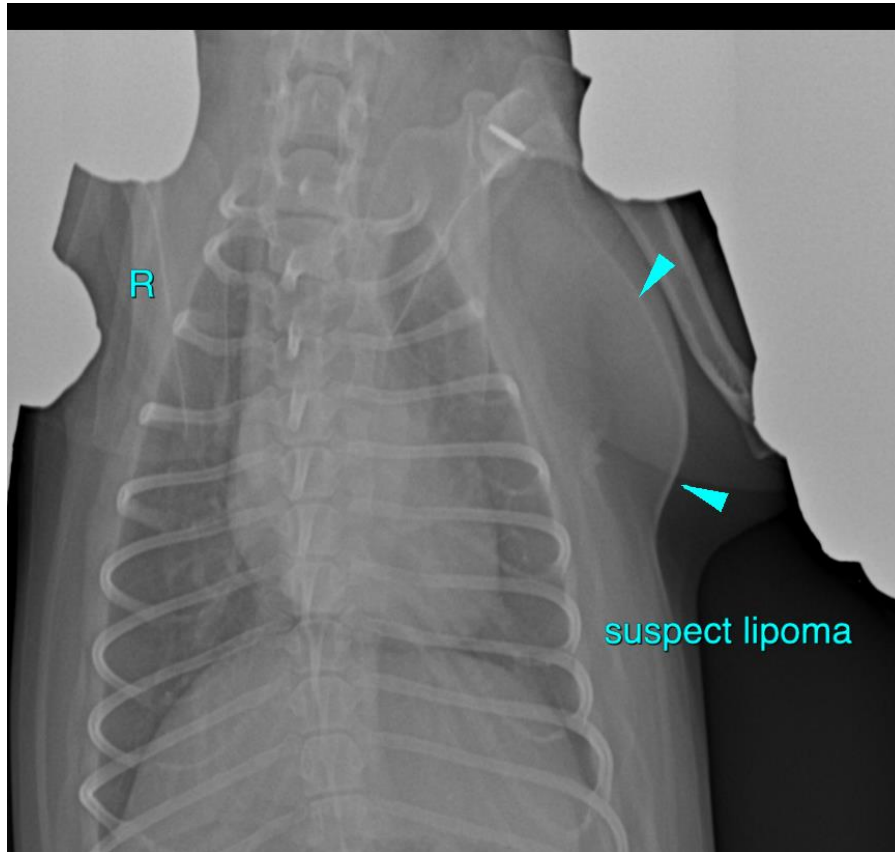
Female

AGE

22 Months

INTERPRETED BY

Sebastian Schaub, DVM
Dr. med. vet. DipECVDI



HOSPITAL NAME

Truscott Animal
Hospital

REFERRING VET

Medhat Meawad

INVOICE

50141

DATE

2-7-22

The information and recommendations provided are based on the images presented by the referring veterinarian/sonographer. No evaluation can be communicated regarding pathology that was not visible in the image/video clips provided.

Thank you for this referral. If the clinical or image interpretation does not parallel your findings or if I can be of any further assistance please contact me.

Sebastian Schaub, Sebastian Schaub, DVM, Dr. med. vet. DipECVDI
sebast.schaub@gmail.com