



## PATIENT

Lyla Jennifer Brooks

## SPECIES

Canine

## BREED

Am. Pitbull Terrier

## SEX

Spayed Female

## AGE

1 Years

## WEIGHT

17.3 kg

## INTERPRETED BY

Sebastian Schaub, DVM  
Dr. med. vet. DipECVDI

## IMAGING PERFORMED BY

Lisa S.

## HOSPITAL NAME

ASC Oceanside

## REFERRING VET

Dr Infernuso

## INVOICE

35764

## DATE

2/6/26

## PRESENTING CLINICAL SIGNS

History: Chronic ear infections.

## COMPUTED TOMOGRAPHIC STUDY OF THE SKULL

A high-resolution plain CT study of the skull is provided for review.

## COMPUTED TOMOGRAPHIC FINDINGS

Triadan 408 is absent.

The nasal cavity presents the expected aerated spaces between thin & even conchae and turbinates with smooth mucosal lining.

Both temporomandibular joints present congruent joint spaces with even subchondral bone surfaces and are considered within normal limits.

Both tympanic bullae are partially obliterated by soft tissue attenuating material and present a thickened, smooth wall. The wall of the ear canals is irregularly thickened and presents advanced shell-like mineralization, L>R.

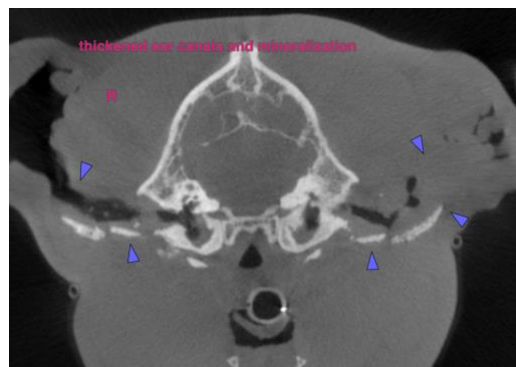The submandibular and medial retropharyngeal lymph nodes are small and elongated with a normal short-to-long-axis-ratio is < 0.5, the attenuation pattern is uniform.

## COMPUTED TOMOGRAPHIC DIAGNOSIS

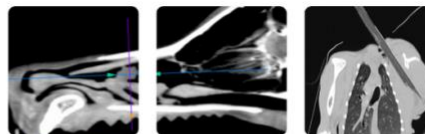
- Bilateral advanced chronic otitis externa, L>R, with dystrophic mineralization
- Bilateral otitis media
- Absent triadan 408

## INTERPRETATION OF THE FINDINGS & FURTHER RECOMMENDATIONS

The CT findings are fitting the history of bilateral chronic otitis externa and secondary otitis media. Surgical management via total ear canal ablation is considered beneficial as the ear canals may be prone to rupture and cause periauricular abscessation.



**The information and recommendations provided are based on the images presented by the referring veterinarian/sonographer. No evaluation can be communicated regarding pathology that was not visible in the image/video clips provided.**



**PATIENT**

Lyla Jennifer Brooks

**SPECIES**

Canine

**BREED**

Am. Pitbull Terrier

**SEX**

Spayed Female

**AGE**

1 Years

**WEIGHT**

17.3 kg

**INTERPRETED BY**

Sebastian Schaub, DVM  
Dr. med. vet. DipECVDI

**IMAGING  
PERFORMED BY**

Lisa S.

**HOSPITAL NAME**

ASC Oceanside

**REFERRING VET**

Dr Infernuso

**INVOICE**

35764

**DATE**

2/6/26

Thank you for this referral. If the clinical or image interpretation does not parallel your findings or if I can be of any further assistance please contact me.

**Sebastian Schaub**, DVM, Dr. med. vet. DipECVDI

[info@sonopath.com](mailto:info@sonopath.com)