

**PATIENT**

Rico Hawks

SPECIES

Canine

BREED

English Shepard

SEX

MN

AGE

6 Years

INTERPRETED BYSebastian Schaub, DVM
Dr. med. vet. DipECVDI**HOSPITAL NAME**Northshore
Veterinary Hospital**REFERRING VET**

Danielle Alleman

INVOICE

56604

DATE

2-6-23

PRESENTING CLINICAL SIGNS

History of bilateral elbow dysplasia and R biceps tendinopathy. O left outside on long line last night, and P came back limping on front leg. O unsure which leg. P not limping today in clinic. O concerned due to P pain tolerance generally being quite high. Elected to do bilateral shoulder and elbow rads

RADIOGRAPHIC STUDY OF THE SHOULDER & ELBOW JOINTS

Radiographs of the shoulder joints in two orthogonal imaging planes and the elbow joints in a mediolateral projection are provided for review.

RADIOGRAPHIC FINDINGS

Both shoulder joints present smooth osseous margins and the surrounding soft tissue structures are within normal limits.

At the proximal aspect of the anconeal process of the right & left elbow joint, moderate osteophyte new bone formation and the cranial aspect of the head of the right radius mild osteophyte new bone formation is seen.

The anconeal process of the left elbow joint presents a shallow double contour.

RADIOGRAPHIC DIAGNOSIS

- Bilateral mild to moderate degenerative osteoarthritis of the elbow joints
- Normal shoulder joints

INTERPRETATION OF THE FINDINGS & FURTHER RECOMMENDATIONS

The radiographic study of the front limbs presents with signs of degenerative joint disease of the elbow joints and acute on chronic insult/increased load might be a source for pain.

The shoulder joints present without abnormalities, however this does not rule out possible tendinopathy of the bicipital tendon or rotator cuff injury.



PATIENT

Rico Hawks

SPECIES

Canine

BREED

English Shepard

SEX

MN

AGE

6 Years

INTERPRETED BY

Sebastian Schaub, DVM
Dr. med. vet. DipECVDI

HOSPITAL NAME

Northshore
Veterinary Hospital

REFERRING VET

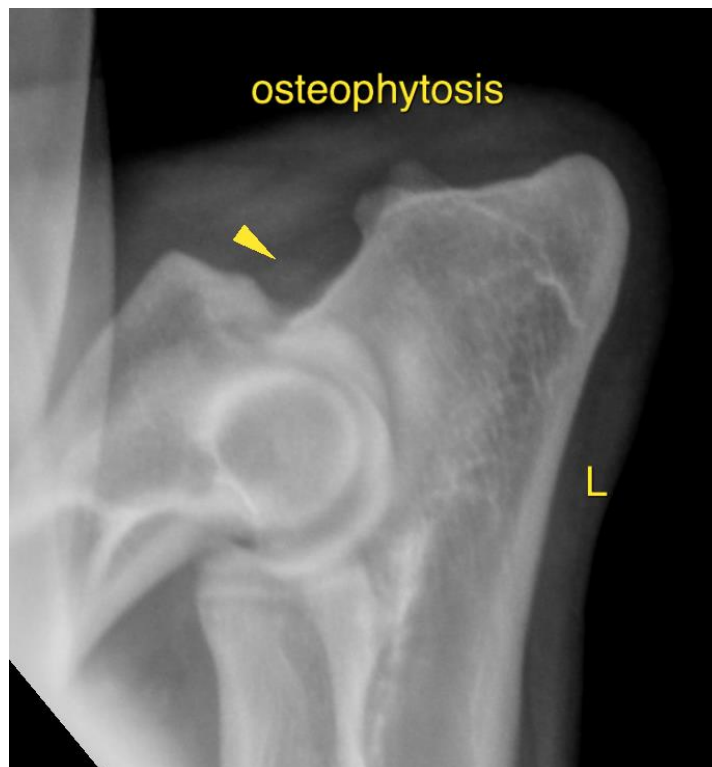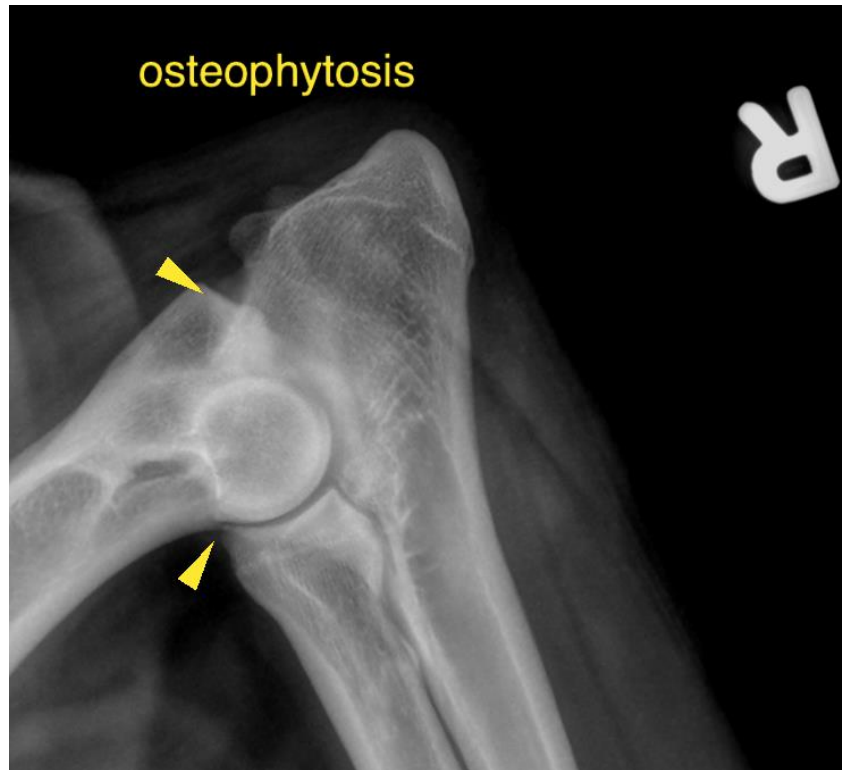
Danielle Alleman

INVOICE

56604

DATE

2-6-23





PATIENT

Rico Hawks

SPECIES

Canine

BREED

English Shepard

SEX

MN

AGE

6 Years

INTERPRETED BY

Sebastian Schaub, DVM
Dr. med. vet. DipECVDI

HOSPITAL NAME

Northshore
Veterinary Hospital

REFERRING VET

Danielle Alleman

INVOICE

56604

DATE

2-6-23

The information and recommendations provided are based on the images presented by the referring veterinarian/sonographer. No evaluation can be communicated regarding pathology that was not visible in the image/video clips provided.

Thank you for this referral. If the clinical or image interpretation does not parallel your findings or if I can be of any further assistance please contact me.

Sebastian Schaub, Sebastian Schaub, DVM, Dr. med. vet. DipECVDI
sebast.schaub@gmail.com