



PATIENT

Simba Crane

SPECIES

Feline

BREED

Domestic Short Hair

SEX

Male Neutered

AGE

7Y

WEIGHT

5.25lbs

INTERPRETED BY

Sebastian Schaub, DVM
Dr. med. vet.
DipECVDI

IMAGING PERFORMED BY

Dr. Abina Glennon

HOSPITAL NAME

New Bridge Veterinary
Practice

REFERRING VET

Dr. Abina Glennon

INVOICE

73641

DATE

2-5-26

PRESENTING CLINICAL SIGNS

- decreased appetite / weakness/lethargicP

Abnormal PE/Chem/CBC/UA Results: labs pending

RADIOGRAPHIC STUDY OF THE THORAX

A right lateral view of the abdomen is provided for review.

RADIOGRAPHIC FINDINGS

The surrounding bony structures are within normal limits.

No abnormalities of the extraabdominal soft tissues are noted. The abdominal wall is smooth and thin.

The serosal detail is decreased due to lack of peritoneal fat.

The liver is appropriate in position, size and presents uniform opacity.

The spleen is not appreciated.

The urinary bladder is in its anticipated position. No radiopaque calculi are noted throughout the upper and lower urinary tract.

The stomach cannot be appreciated caudal to the liver. Cranial to the liver, superimposed on the caudal aspect of the thorax, foamy soft tissue material is appreciated. The cranial contour of the diaphragm is well-defined.

The small intestinal loops are of even diameter and non-dilated, a small amount of gas is seen within the small intestinal loops and considered within normal limits.

The colon is seen in the expected position and presents with appropriate content.

RADIOGRAPHIC DIAGNOSIS

- Cranial malposition of the stomach

INTERPRETATION OF THE FINDINGS & FURTHER RECOMMENDATIONS

The malposition of the stomach cranial to the liver can be caused by diaphragmatic hernia (check for possible traumatic insult) or eventration of the left hemidiaphragm (may explain the relatively well-defined cranial convex shaped border). A CT study would be ideal for specification. If not applicable a radiographic study in a VD view may provide additional information as well.



PATIENT

Simba Crane

SPECIES

Feline

BREED

Domestic Short Hair

SEX

Male Neutered

AGE

7Y

WEIGHT

5.25lbs

INTERPRETED BY

Sebastian Schaub, DVM
Dr. med. vet.
DipECVDI

IMAGING PERFORMED BY

Dr. Abina Glennon

HOSPITAL NAME

New Bridge Veterinary
Practice

REFERRING VET

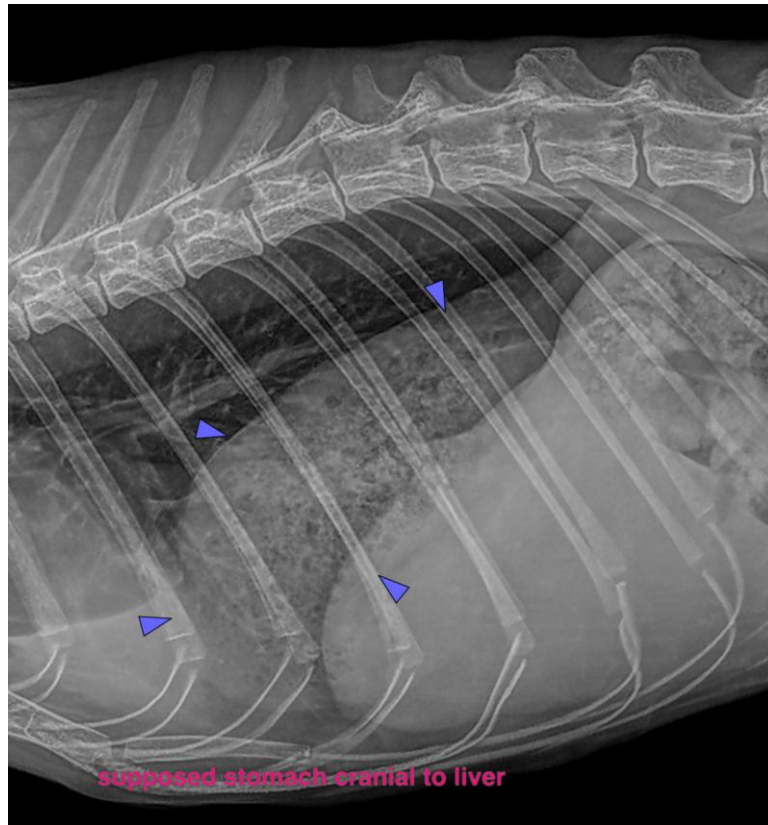
Dr. Abina Glennon

INVOICE

73641

DATE

2-5-26



The information and recommendations provided are based on the images presented by the referring veterinarian/sonographer. No evaluation can be communicated regarding pathology that was not visible in the image/video clips provided.

Thank you for this referral. If the clinical or image interpretation does not parallel your findings or if I can be of any further assistance please contact me.

Sebastian Schaub, Sebastian Schaub, DVM, Dr. med. vet. DipECVDI
info@sonopath.com