



## PATIENT

Cicero Ishikawa

## SPECIES

Feline

## BREED

DSH

## SEX

Male Neutered

## AGE

9Y, 9M

## WEIGHT

13.47

## INTERPRETED BY

Sebastian Schaub, DVM  
Dr. med. vet.  
DipECVDI

## IMAGING PERFORMED BY

Kristan Swinford

## HOSPITAL NAME

Queen Creek  
Veterinary Clinic

## REFERRING VET

Kelsey Sampayan

## INVOICE

73642

## DATE

2-5-26

## PRESENTING CLINICAL SIGNS

- original exam 09/04/25 for sneezing and shaking head; was on prednisolone at the time
- per owner p frequently shakes his head and exam showed mild erythema and excoriation of external pinna, mild erythema of external ear canal, moderate amount of purulent discharge, intact tympanum
- discussed Otitis externa AU - purulent discharge, intact tympanum AU; cannot r/o extension to middle or inner ears or possibility of polyp at this time
- 09/12/25 recheck - Otitis externa - resolved - Owner reports sneezing, URI, and head shaking has improved. Discussed there is still a potential for polyps but since clinical signs have improved, recommend monitoring pt for now.

Abnormal PE/Chem/CBC/UA Results: Pre op BW WNL PE - NSF today

## COMPUTED TOMOGRAPHY OF THE SKULL

A high resolution pre- and post-contrast CT study of the skull is provided for review.

## COMPUTED TOMOGRAPHIC FINDINGS

Triadan 301 is absent. The crown of triadan 102 is absent.

In the caudal aspect of the nasal cavity, a small to moderate amount of fluid attenuating material is attached to the nasal mucosal lining and mucosal lining of the sphenoid sinus.

Both temporomandibular joints present congruent joint spaces with even subchondral bone surfaces and are considered within normal limits.

Both tympanic bullae are aerated, the mucosal lining is not seen, the bony wall is smooth and thin. The external ear canals are within normal limits.

The brain presents no deviation from normal anatomy and symmetry. The brain parenchyma is homogeneous and within normal limits for attenuation and distribution of contrast enhancement. The ventricular system is non-dilated and symmetric.

The submandibular and medial retropharyngeal lymph nodes are small and elongated with a normal short-to-long-axis-ratio is < 0.5, the attenuation and contrast enhancement pattern is uniform.

## COMPUTED TOMOGRAPHIC DIAGNOSIS

- Mild rhinitis and sinusitis sphenoid sinus
- Complicated dental fracture 102
- Absent triadan 301
- No evidence of otitis media nor inflammatory nasopharyngeal polyp formation

## INTERPRETATION OF THE FINDINGS & FURTHER RECOMMENDATIONS

Rhinitis in feline patients is commonly primary viral ± bacterial superinfection; a differential is non-specific rhinitis (e.g. lymphoplasmacytic, eosinophilic). Rhinoscopy including biopsy and sampling for microbial culture - in many cases the initial causative infectious agent cannot be isolated anymore - can be used as advanced diagnostic tool.



## PATIENT

Cicero Ishikawa

## SPECIES

Feline

## BREED

DSH

## SEX

Male Neutered

## AGE

9Y, 9M

## WEIGHT

13.47

## INTERPRETED BY

Sebastian Schaub, DVM  
Dr. med. vet.  
DipECVDI

## IMAGING PERFORMED BY

Kristan Swinford

## HOSPITAL NAME

Queen Creek  
Veterinary Clinic

## REFERRING VET

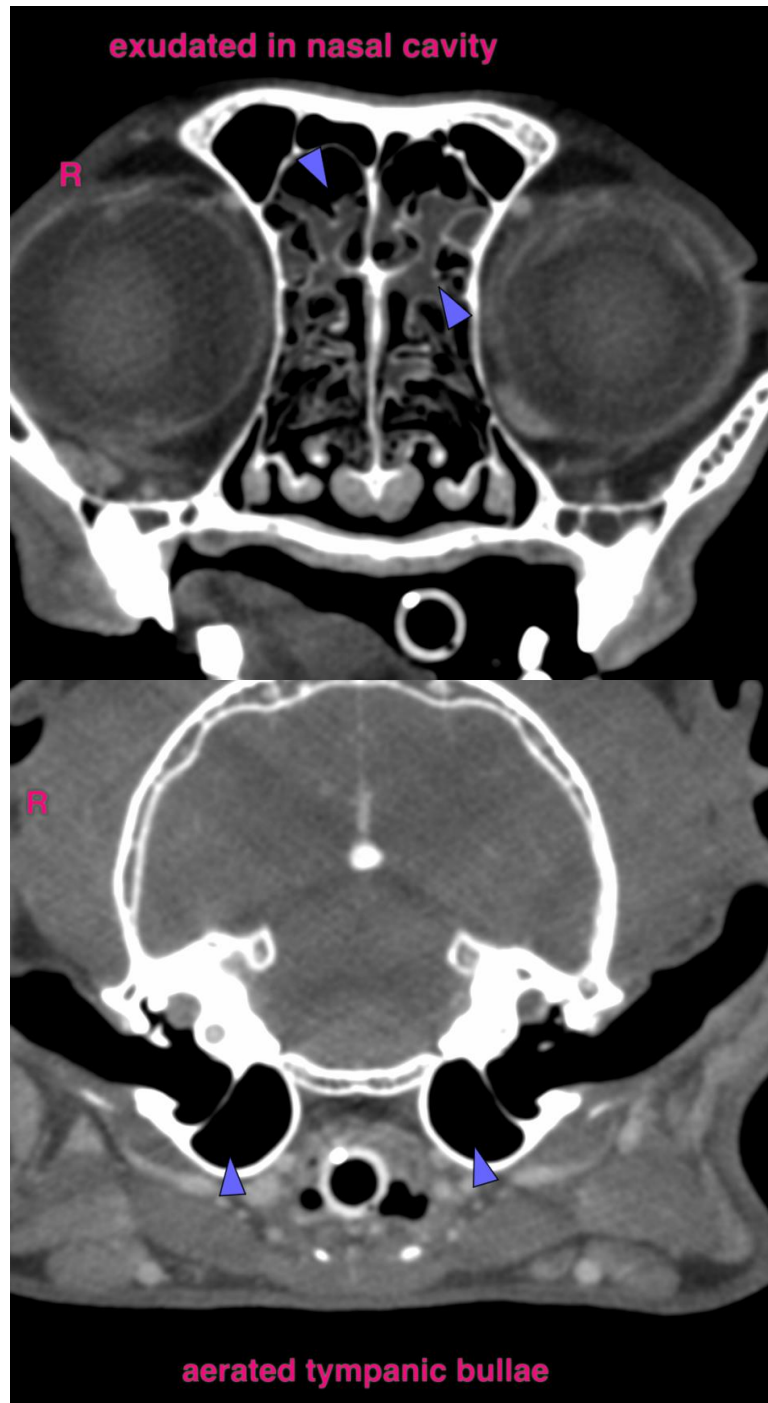
Kelsey Sampayan

## INVOICE

73642

## DATE

2-5-26





## PATIENT

Cicero Ishikawa

## SPECIES

Feline

## BREED

DSH

## SEX

Male Neutered

## AGE

9Y, 9M

## WEIGHT

13.47

## INTERPRETED BY

Sebastian Schaub, DVM  
Dr. med. vet.  
DipECVDI

## IMAGING PERFORMED BY

Kristan Swinford

## HOSPITAL NAME

Queen Creek  
Veterinary Clinic

## REFERRING VET

Kelsey Sampayan

## INVOICE

73642

## DATE

2-5-26

The information and recommendations provided are based on the images presented by the referring veterinarian/sonographer. No evaluation can be communicated regarding pathology that was not visible in the image/video clips provided.

Thank you for this referral. If the clinical or image interpretation does not parallel your findings or if I can be of any further assistance please contact me.

**Sebastian Schaub**, Sebastian Schaub, DVM, Dr. med. vet. DipECVDI  
[info@sonopath.com](mailto:info@sonopath.com)