



PATIENT

Ronaldo Gorena

PRESENTING CLINICAL SIGNS

Lethargic. Vomiting past two days. Hasn't eaten or drank in almost 48 hours. Had access to small toys, could have eaten it.

SPECIES

Feline

RADIOGRAPHIC STUDY OF THE ABDOMEN

Radiographs of the abdomen in three imaging planes are provided for review.

BREED

Russian Blue

RADIOGRAPHIC FINDINGS

Six lumbar vertebra are present. The last thoracic vertebra presents with a normal rib on the left side and a floating rib in the right aspect.

SEX

Male Neutered

No abnormalities of the extraabdominal soft tissues are noted. The abdominal wall is smooth and thin.

The serosal detail is maintained throughout the peritoneal and retroperitoneal space.

The liver is appropriate in position, size and presents uniform opacity.

AGE

2 Years

The splenic head is in the anticipated position and within normal limits for size and opacity.

Both kidneys are seen and present with normal size, shape, delineation and opacity. The urinary bladder is in its anticipated position. No radiopaque calculi are noted throughout the upper and lower urinary tract.

INTERPRETED BY

Sebastian Schaub, DVM
Dr. med. vet. DipECVDI

The stomach is in its anticipated position and presents normal content.

HOSPITAL NAME

Truscott Animal Hospital

In the right cranial and caudal abdomen, gas and fluid filled, moderately dilated small intestinal loops are present. There is a second population of small intestinal loops with normal diameter. In the right lateral projection of the abdomen, a fine granular appearing soft tissue and gas opaque structure is visible, not appreciated in the other views.

The colon is seen in the expected position and presents with appropriate content.

REFERRING VET

Dr. Medhat Meawad

RADIOGRAPHIC DIAGNOSIS

- Suspect segmental small intestinal mechanical obstruction

INTERPRETATION OF THE FINDINGS & FURTHER RECOMMENDATIONS

INVOICE

50076

The radiographic study is highly suggestive for small intestinal mechanical obstruction with foreign material lodged in a jejunal segment. Surgical intervention can be justified with the current radiographic findings, in case of doubt ultrasound can be used to confirm the diagnosis.

DATE

2-5-22



PATIENT

Ronaldo Gorena

SPECIES

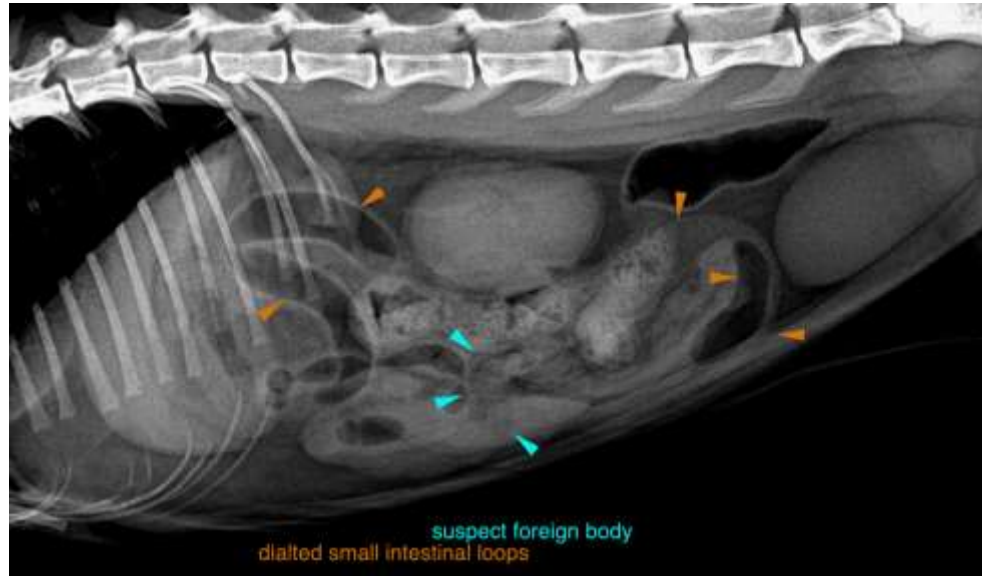
Feline

BREED

Russian Blue

SEX

Male Neutered



AGE

2 Years

INTERPRETED BY

Sebastian Schaub, DVM
Dr. med. vet. DipECVDI

HOSPITAL NAME

Truscott Animal
Hospital

REFERRING VET

Dr. Medhat Meawad

INVOICE

50076

DATE

2-5-22

The information and recommendations provided are based on the images presented by the referring veterinarian/sonographer. No evaluation can be communicated regarding pathology that was not visible in the image/video clips provided.

Thank you for this referral. If the clinical or image interpretation does not parallel your findings or if I can be of any further assistance please contact me.

Sebastian Schaub, Sebastian Schaub, DVM, Dr. med. vet. DipECVDI
sebast.schaub@gmail.com