



PATIENT PRESENTING CLINICAL SIGNS

PATIENT Chewie Musngi
PRESENTING CLINICAL SIGNS was choking today and heavy breathing , change on barking pitch owner is worried he might be choking on something

SPECIES RADIOGRAPHIC STUDY OF THE NECK

SPECIES Canine
RADIOGRAPHIC STUDY OF THE NECK Radiographs of the neck in two imaging planes are provided for review.

RADIOGRAPHIC FINDINGS

BREED

Pomeranian

A moderate amount of gas is seen along the soft retropharyngeal soft tissue structures and dissecting caudally along the fascial planes of the neck – accentuating the tracheal margins.

SEX

MN

The larynx is in a relative caudal position level with C3, and the hyoid apparatus is deviated to the left and appears asymmetric. The thyrohyoid bone appears to be detached from the thyroid cartilage.

RADIOGRAPHIC DIAGNOSIS

AGE

6

- Emphysema retropharyngeal area, extending caudally along the fascial planes of the neck
- Caudal position of the pharynx
- Possible fracture/avulsion of hyoid apparatus

INTERPRETED BY

Sebastian Schaub, DVM
 Dr. med. vet. DipECVDI

INTERPRETATION OF THE FINDINGS & FURTHER RECOMMENDATIONS

HOSPITAL NAME

CJAH

The findings are highly suggestive for traumatic laceration of the pharynx/larynx with possible avulsion of the thyrohyoid bone from the thyroid cartilage. The radiographic changes are concerning for preceding traumatic insult with secondary laceration of the pharyngeal soft tissues – rule out bite injury, stick injury, strangulation, blunt traumatic insult, other. No radiopaque foreign material is appreciated. If not done so yet, visual evaluation of the laryngeal and pharyngeal area is indicated to localize soft tissue defects allowing gas dissect into the soft tissues. A CT might be used to further evaluation of the osseous structures of the hypoid apparatus.

REFERRING VET

Gabriel

Based on the findings of the advanced diagnostic test, surgical intervention appears indicated.

INVOICE

50078

DATE

2-5-22



PATIENT

Chewie Musngi

SPECIES

Canine

BREED

Pomeranian

SEX

MN

AGE

6

INTERPRETED BY

Sebastian Schaub, DVM
Dr. med. vet. DipECVDI

HOSPITAL NAME

CJAH

REFERRING VET

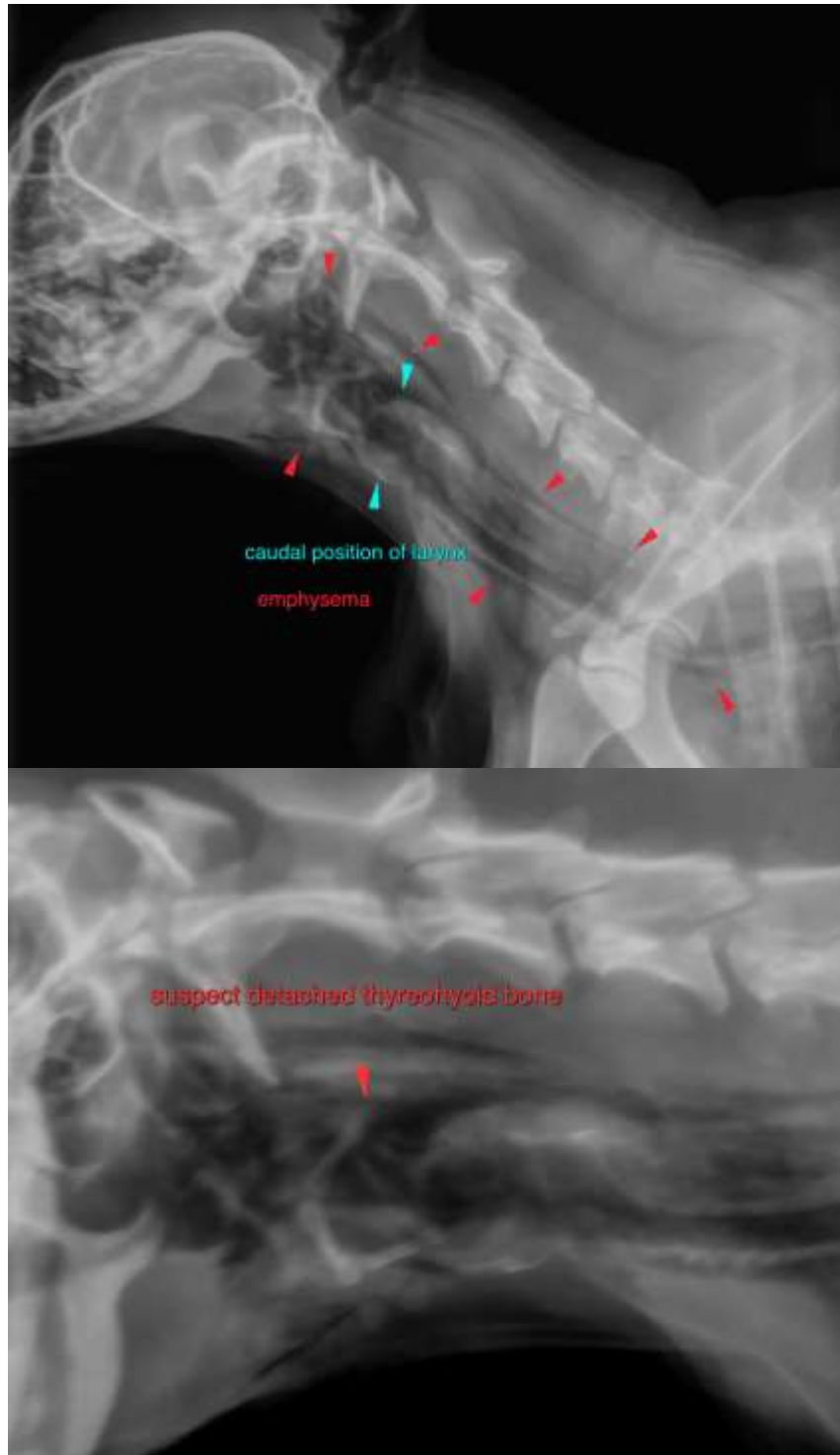
Gabriel

INVOICE

50078

DATE

2-5-22





PATIENT

Chewie Musngi

The information and recommendations provided are based on the images presented by the referring veterinarian/sonographer. No evaluation can be communicated regarding pathology that was not visible in the image/video clips provided.

SPECIES

Canine

Thank you for this referral. If the clinical or image interpretation does not parallel your findings or if I can be of any further assistance please contact me.

BREED

Pomeranian

Sebastian Schaub, Sebastian Schaub, DVM, Dr. med. vet. DipECVDI
sebast.schaub@gmail.com

SEX

MN

AGE

6

INTERPRETED BY

Sebastian Schaub, DVM
Dr. med. vet. DipECVDI

HOSPITAL NAME

CJAH

REFERRING VET

Gabriel

INVOICE

50078

DATE

2-5-22