



PATIENT

Jax Fowles

SPECIES

Feline

BREED

DSH

SEX

MN

AGE

5.5Y

WEIGHT

12lbs

INTERPRETED BY

Sebastian Schaub, DVM
Dr. med. vet.
DipECVDI

IMAGING PERFORMED BY

Jen Amidon

HOSPITAL NAME

The Pet Hospital of
Stratford

REFERRING VET

Dr. David

INVOICE

73623

DATE

2-4-26

PRESENTING CLINICAL SIGNS

History:

- Pt presented a week after being partially blocked.
- Xrays to r/o stones
- Cysto for urine collection done prior to xrays

RADIOGRAPHIC STUDY OF THE ABDOMEN

Radiographs of the abdomen in three imaging planes are provided for review.

RADIOGRAPHIC FINDINGS

The surrounding bony structures are within normal limits.

No abnormalities of the extraabdominal soft tissues are noted. The abdominal wall is smooth and thin.

The serosal detail is maintained throughout the peritoneal and retroperitoneal space.

The liver is appropriate in position, size and presents uniform opacity.

The splenic head is in the anticipated position and within normal limits for size and opacity. The splenic body and tail are considered normal for position, size, shape and opacity.

Both kidneys are seen and present with normal size, shape, delineation and opacity. The urinary bladder is in its anticipated position and a small gas bubble, and three mineral opaque calculi are appreciated in the image plane of the urinary bladder.

The stomach is in its anticipated position and presents normal content.

The small intestinal loops are of even diameter and non-dilated, a small amount of gas is seen within the small intestinal loops and considered within normal limits.

The colon is seen in the expected position and presents with appropriate content.

RADIOGRAPHIC DIAGNOSIS

- Cystolithiasis
- Small amount of gas in urinary bladder – iatrogenic due to preceding cystocentesis

INTERPRETATION OF THE FINDINGS & FURTHER RECOMMENDATIONS

The radiographic study reveals multiple small mineral opaque calculi within the urinary bladder (e.g. struvite, calcium oxalate) that can cause the presenting clinical signs. Complete urinalysis has already been performed.



PATIENT

Jax Fowles

SPECIES

Feline

BREED

DSH

SEX

MN

AGE

5.5Y

WEIGHT

12lbs

INTERPRETED BY

Sebastian Schaub, DVM
Dr. med. vet.
DipECVDI

IMAGING PERFORMED BY

Jen Amidon

HOSPITAL NAME

The Pet Hospital of
Stratford

REFERRING VET

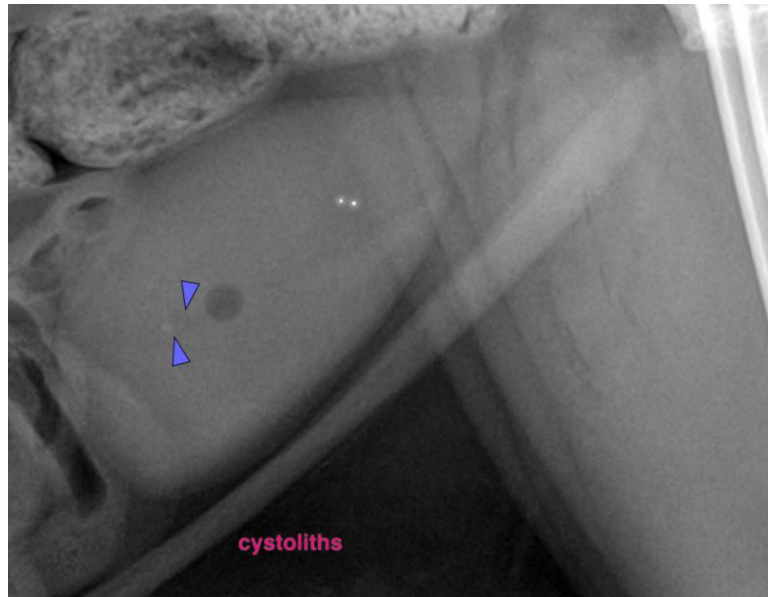
Dr. David

INVOICE

73623

DATE

2-4-26



The information and recommendations provided are based on the images presented by the referring veterinarian/sonographer. No evaluation can be communicated regarding pathology that was not visible in the image/video clips provided.

Thank you for this referral. If the clinical or image interpretation does not parallel your findings or if I can be of any further assistance please contact me.

Sebastian Schaub, Sebastian Schaub, DVM, Dr. med. vet. DipECVDI

info@sonopath.com